

A rare case of intracranial brain mass with an unexpected diagnosis: Hydatid cyst

Hakan Tuncer, Furkan Parlak, Betül Çam, Hatice Karaçam, Abuzer Coskun*, Burak Akın and Burak Demirci

Emergency Medicine, Health Sciences University, Istanbul Bagcilar Training and Research Hospital, 34200, Istanbul, Turkey.

Accepted 4 April, 2023

ABSTRACT

The hydatid cyst remains a common disorder in areas where it is endemic. The prognosis is greatly improved by early diagnosis and treatment, thus accurate differential diagnosis is essential. Since hydatid cysts are frequently misdiagnosed or underdiagnosed, it is essential to thoroughly investigate their clinical and imaging characteristics. In this article, we highlighted the diagnostic and therapeutic steps that led to the identification of a hydatid cyst, which had previously been misdiagnosed despite consistent clinical and radiological evidence.

Keywords: Hydatid cyst, liver, brain, emergency department.

*Corresponding author. E-mail: dr.acoskun44@hotmail.com. Tel: + 90 (212) 440 40 00. Fax: + 90 (212) 440 42 42. Mobile: +90 532 157 79 12.

Abbreviations: **GCS:** Glasgow Coma Scale, **CT:** Computed Tomography, **MRI:** Magnetic Resonance Imaging, **DNA:** Deoxyribonucleic Acid, **WBC:** White Blood Cell, **ALP:** Alkaline Phosphatase, **GGT:** Gamma-Glutamyl Transferase, **AST:** Aspartate Aminotransferase, **ALT:** Alanine Aminotransferase.

INTRODUCTION

Cystic echinococcosis caused by a zoonotic infection of the larval stage of cestode species *Echinococcus granulosus*, and is the most common type of the disease prevalent worldwide, particularly in pastoral regions where sheep, goats and other livestock are raised. Humans are accidental intermediate hosts that become infected by ingesting worm eggs, which were produced by the definitive host harboring adult worms, and shed in the stool that contaminate soil, dirt or animal hair around farmers' dwellings (Shafiei et al., 2016; Moro and Schantz, 2009; Mahmoudi et al., 2019). Most infections in people are asymptomatic unless complications occur. Hydatid cysts can localize in virtually any organ and structure, such as primarily in the liver affecting 70% of the cases, and in the lung in about 20% of cases, while rarely in the kidney, spleen, bone, brain, eye, ovary, testis, and pancreas. The brain is involved in less than 2% of cases (Fasihi Harandi et al., 2012; Chen et al.,

2018). On radiographs, the cyst manifests as a single or several, round or oval well-circumscribed mass lesions. Surgery has been the mainstay approach of treatment, but alternatives are of choice for selected patients. If there are cysts in multiple organs or tissues, or the cysts are in risky locations, surgery becomes impractical. For those inoperable cases, chemotherapy with albendazole becomes an alternative option for treatment (Fattahi Masoom et al., 2018; Bakhsh et al., 2017).

CASE PRESENTATION

A 69-year-old male presented to the emergency department with a one-week history of headaches. Physical examination revealed stable vital signs, a Glasgow Coma Scale (GCS) of 15 (E4, V5, M6), and an unremarkable systemic physical condition. The patient

underwent head computed tomography (CT) and magnetic resonance imaging (MRI). In the right occipital lobe, an edematous solid lesion was observed (Figure 1). Thoracic and abdominal CT scans were performed to identify the primary malignant lesion. Multiple nodular lesions and a cavitary lesion at the base of the right lung were discovered (Figure 2). In addition, the abdominal CT revealed a 130 × 125 mm mass in the liver's right lobe (Figure 3). The patient suspected of having brain and lung metastases from a liver tumor was referred to the oncology outpatient clinic. The oncology clinic delivered 10 radiotherapy sessions to the patient's head. The patient was then referred to the pulmonology outpatient clinic after it was discovered that he had several masses in his right lung. A necrotizing granulomatous inflammation was found in the biopsy material obtained from the tumor on his right lung. The broncho-alveolar lavage of the patient was used to collect samples for culture. The patient was suspected of having tuberculosis based on the results of the biopsy. As an empirical tuberculosis treatment, daily Isoniazid 5 mg/kg, Pyrazinamide 30 mg/kg, Rifampicin 10 mg/kg, and Ethambutol 20 mg/kg were administered to the patient. The patient's lavage sample was negative for *Mycobacterium tuberculosis* deoxyribonucleic acid (DNA). The patient returned to the emergency department with complaints of fever, walking problems, and headache. His general condition deteriorated and he appeared lethargic, GCS: 14 (E3, V5, M6). The patient's vital parameters were as follows: a body temperature of 38°C, heart rate of 114/min, blood pressure of 105/75 mmHg, the respiration rate of 19/min, and SpO₂ of 95%. Tests for uric acid and electrolytes, viral indicators, blood glucose, and kidney function were all within normal ranges. White blood cell (WBC) 13.5

10³/uL, Eosinophil 0.83 10³/uL, Hgb 14.2 g/dl, platelet 292 10³/uL, alkaline phosphatase (ALP) 125 U/L, gamma-glutamyl transferase (GGT) 81 U/L, aspartate aminotransferase (AST) 53 U/L, and alanine aminotransferase (ALT) 57 U/L were recorded in laboratory examinations. The MRI of the brain, and CT of the thorax and abdomen all exhibited characteristics consistent with a cystic mass. The patient was transferred to the infectious diseases unit for further evaluation and treatment. The liver and lung cysts were biopsied using fine-needle aspiration. *Echinococcus granulosus* was detected in the examined samples. The patient was found to be a farmer who raised sheep and goats when queried about his profession. The patient's medical history revealed that three years prior, he had visited the hospital complaining of knee pain. A cystic lesion was detected on the MRI that was done for this reason (Figure 4). The cause of this cyst has not been investigated further. Nonsteroidal anti-inflammatory drugs were given out simply as a bandage till the pain subsided. After stopping the tuberculosis treatment, the patient began taking albendazole 800 mg daily. The patient was advised to have the cyst removed surgically but ultimately decided against it. The patient was discharged from the hospital after two weeks with a better general condition and a normal level of awareness. The treatment with 800 mg of albendazole per day was maintained for four months. During his four-month follow-up appointment, the patient's general condition and vital signs were stable. No active complaints were presented. For diagnostic purposes, the patient underwent both a CT scan of the chest and abdomen and an MRI of the brain. Scan results for brain, abdominal, and thoracic lesions improved (Figures 5, 6 and 7).

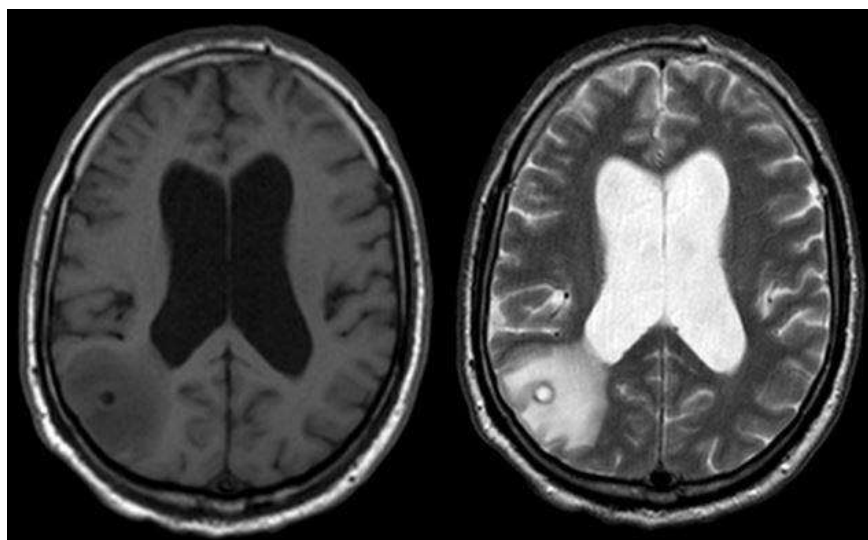


Figure 1. Edematous solid lesion in the right occipital lobe.

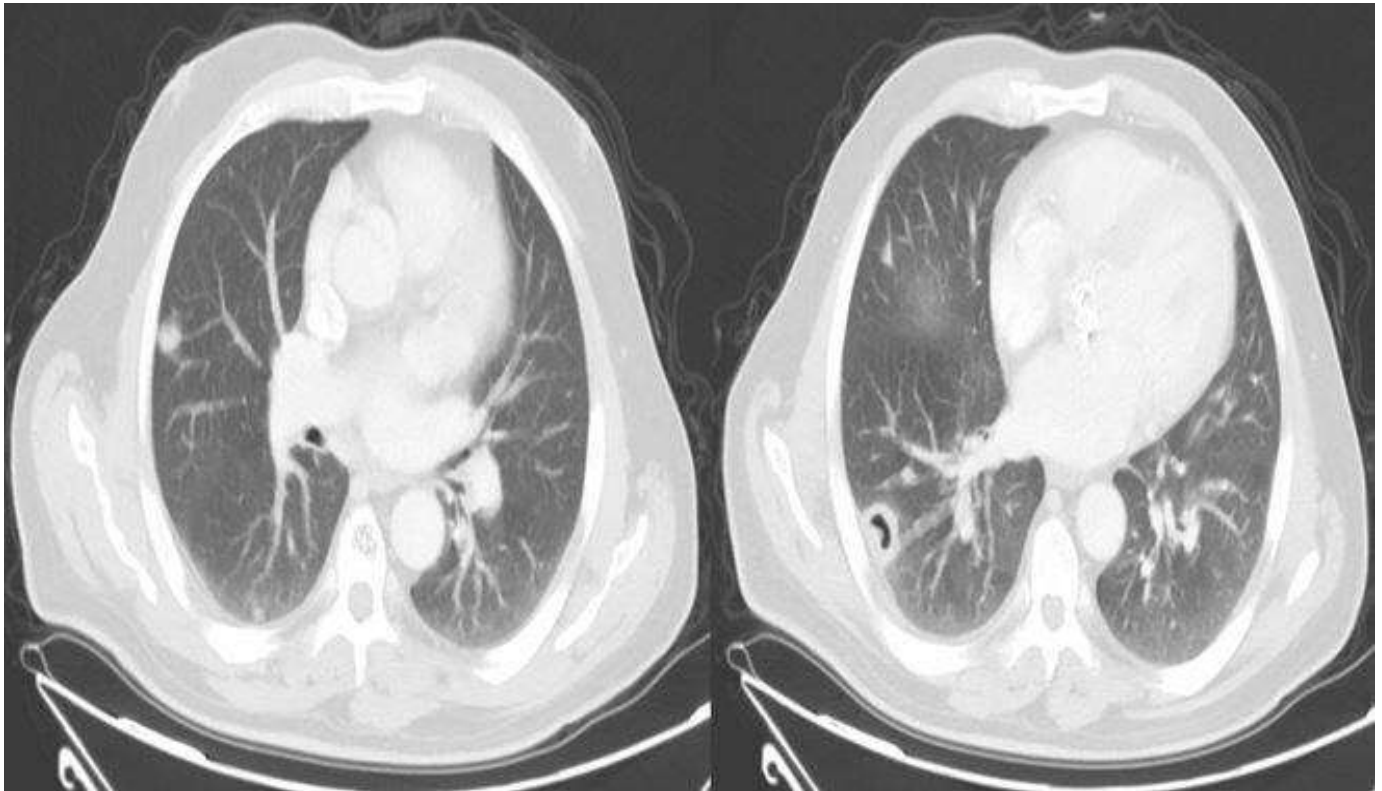


Figure 2. Multiple nodular lesions and a cavitary lesion at the base of the right lung.

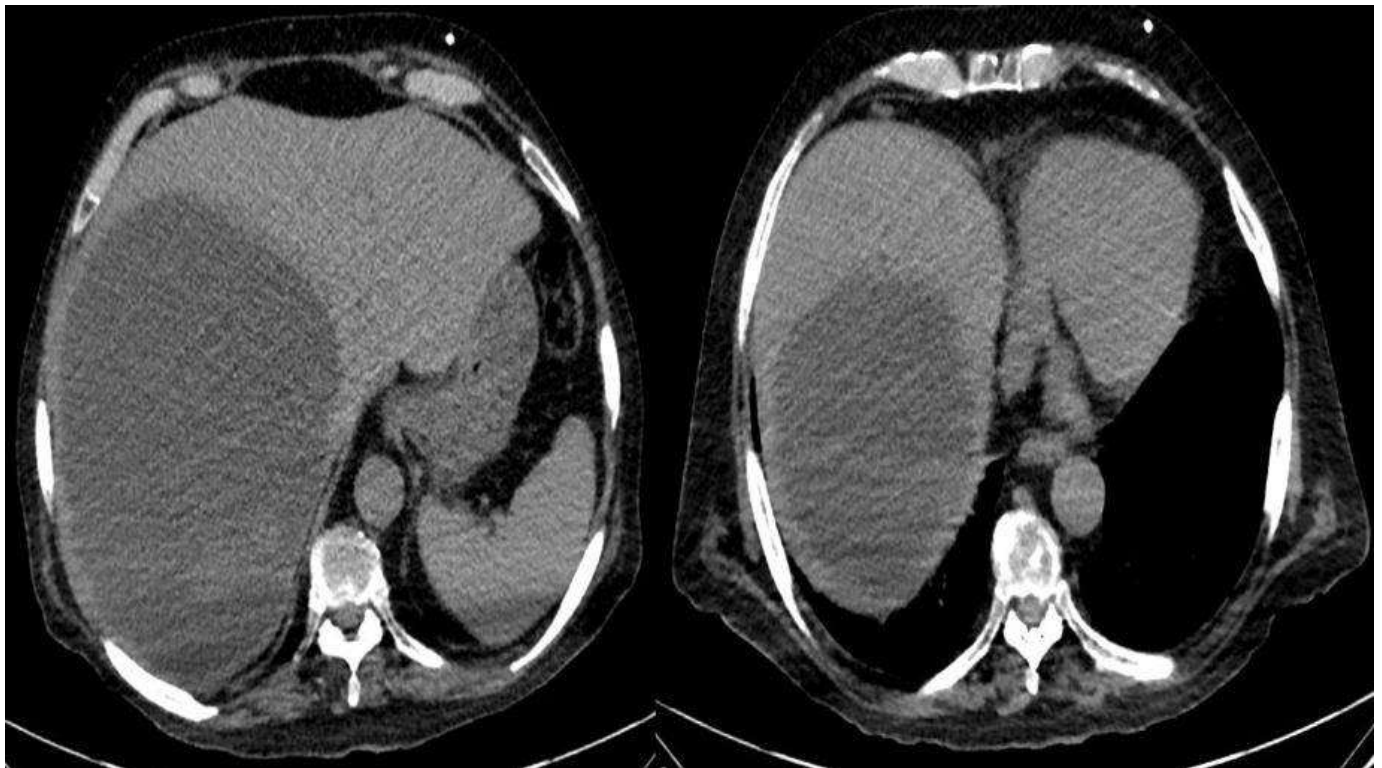

Figure 3. 130 × 125 mm mass in the liver's right lobe on abdominal CT.

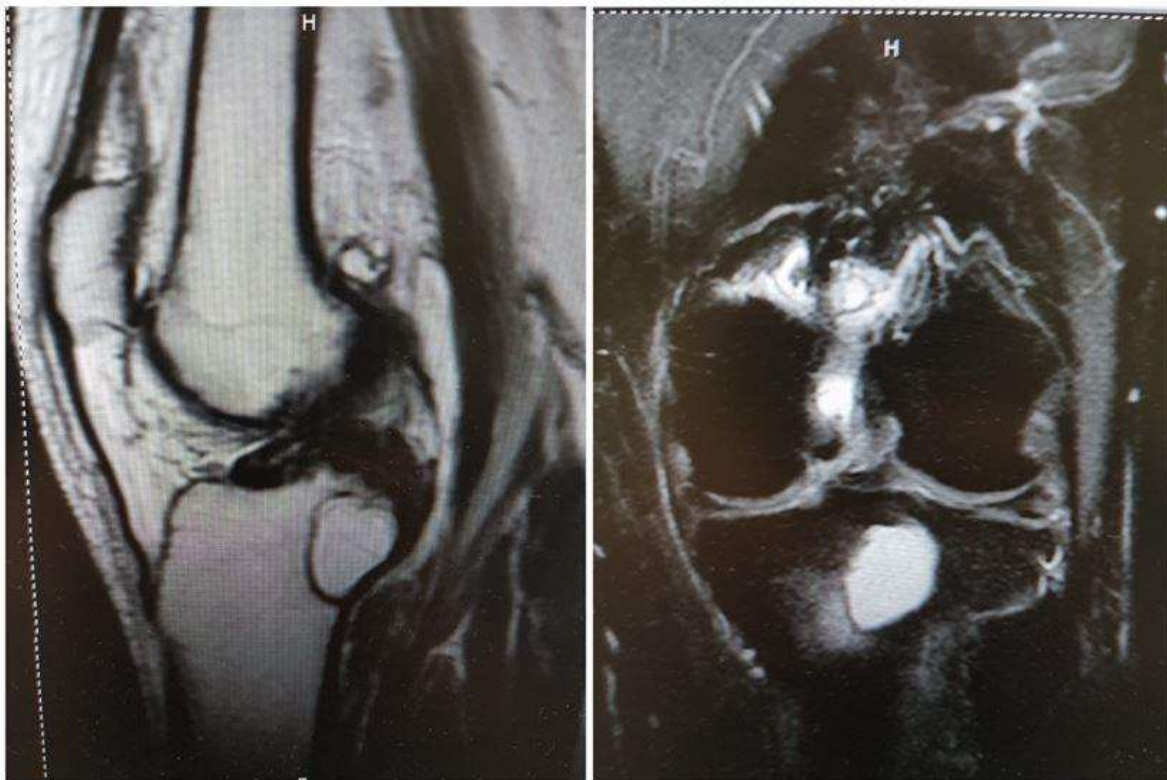


Figure 4. Cystic lesion on knee MRI imaging.

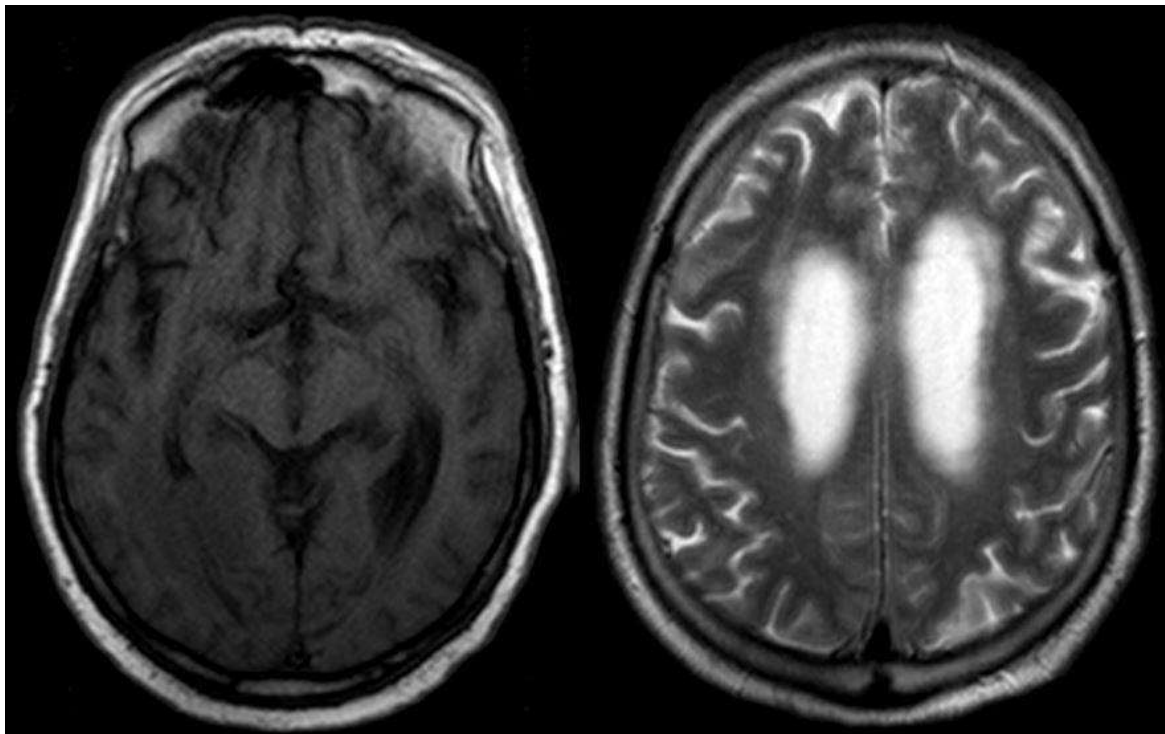


Figure 5. Brain MRI image at follow-up examination.

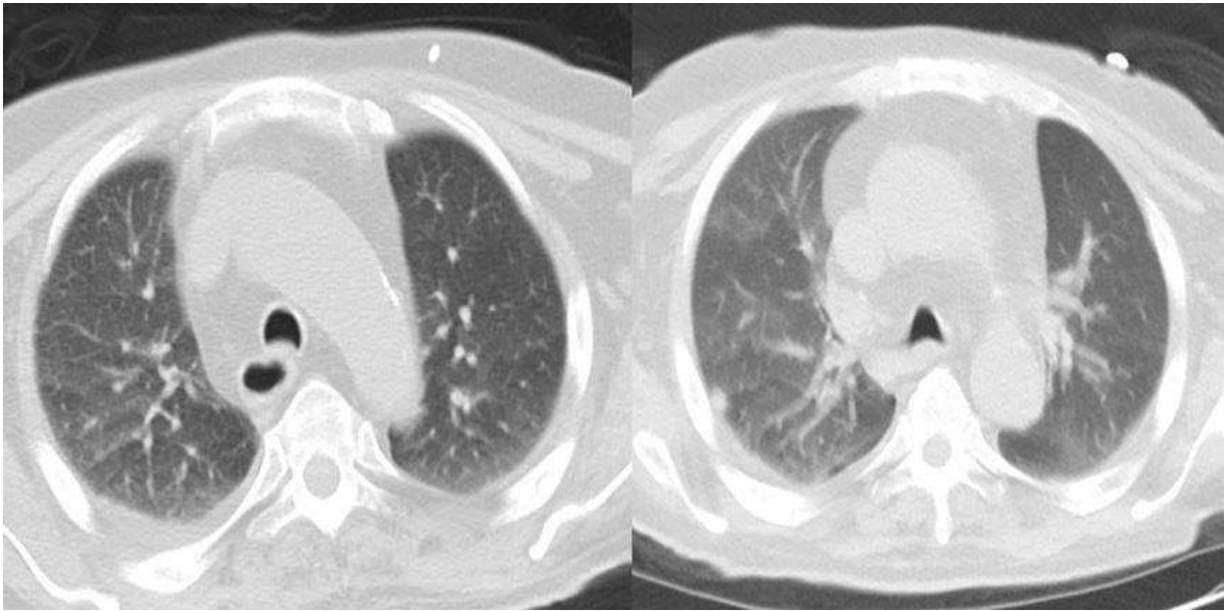


Figure 6. Thorax CT image at control examination.

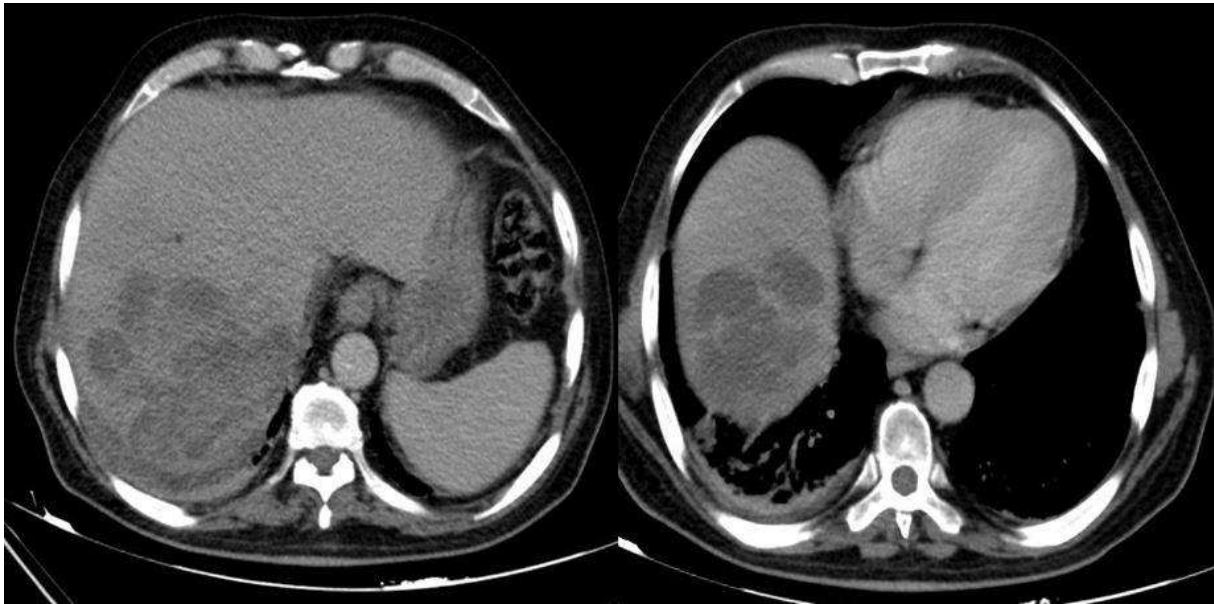

Figure 7. Abdomen CT image at control examination.

DISCUSSION

Cystic hydatid disease is a major public health issue in endemic areas (Mahmoudi et al., 2019). The illness may or may not present any symptoms at all in its early stages. Cysts that are found in the liver have the potential to cause symptoms such as nausea, vomiting, itching, jaundice, and discomfort in the upper right quadrant of

the abdomen (Sadjjadi et al., 2013). Respiratory discomfort, cough, bleeding from the mouth, and chest pain are symptoms of lung involvement, while headache, seizure, and change of consciousness are symptoms of brain involvement (Padayachy and Dattatraya, 2018). Treatment is critical for symptom relief and illness recovery. Surgery is the first-line treatment. Another therapy option is benzimidazole group medicines such as

albendazole (Kabatas et al., 2009). Imaging tests are the initial step in the diagnosis process for hydatid cyst disease (Wani et al., 2011). However, images of the cyst may be misinterpreted as tumors, abscesses, or cavitary lesions (Izci et al., 2008). In order to make an accurate diagnosis of the condition, the infectious agent must be located within the cystic material. If the patient's medical history and occupation had been thoroughly questioned in this instance, it is possible that it would have been discovered that the patient had a cystic lesion in the knee and that the patient's occupation was farming. In addition, the cystic lesion could have been discovered earlier. As a direct consequence of this, a quicker diagnosis of hydatid disease might be made for the patient. If the illness is not detected, it may remain dormant in the body for years, during which time it will cause significant symptoms and issues because treatment will not be begun (Sarkari and Rezaei, 2015). It is essential to be able to recognize a hydatid cyst in order to prevent unnecessary surgeries, prolonged use of antibacterial agents, and a longer hospital stay than would otherwise be necessary (Ullah et al., 2020).

In conclusion, imaging anomalies such as mass-forming lesions should trigger the examination of an infectious etiology, particularly in clinical conditions that are not completely clear. It is vital to acknowledge that people who live in endemic regions have a higher risk of developing hydatid cysts in order to be able to administer treatment that is both appropriate and effective.

REFERENCES

- Bakhsh A, KMA S, Taraif S, 2017.** Primary hydatid cyst of pineal region of brain: a case report from Saudi Arabia. *Asian J Neurosurg*, 12: 314–7.
- Chen S, Li N, Yang F, Wu J, Hu Y, Yu S, Chen Q, Wang X, Wang X, Liu Y, Zheng J, 2018.** Medical treatment of an unusual cerebral hydatid disease. *BMC Infect Dis*, 18: 12.
- Fasihi Harandi M, Budke CM, Rostami S, 2012.** The monetary burden of cystic echinococcosis in Iran. *PLoS Negl Trop Dis*, 6: e1915.
- Fattahi Masoom SH, Lari SM, Fattahi AS, Ahmadnia N, Rajabi M, NaderiKalat M, 2018.** Albendazole therapy in human lung and liver hydatid cysts: A 13-year experience. *Clin Respir J*, 12: 1076-83.
- Izci Y, Tüzün Y, Seçer Hİ, Gönül E, 2008.** Cerebral hydatid cysts: technique and pitfalls of surgical management. *Neurosurg Focus*, 24: e15.
- Kabatas S, Yilmaz C, Cansever T, Gulsen S, Sonmez E, Altinors MN, 2009.** The management of a complicated brain hydatid cyst: case report. *Neurol Neurochir Pol*, 43: 575–8.
- Mahmoudi S, Mamishi S, Banar M, Pourakbari B, Keshavarz H, 2019.** Epidemiology of echinococcosis in Iran: a systematic review and meta-analysis. *BMC Infect Dis*, 19: 929.
- Moro P, Schantz PM, 2009.** Echinococcosis: a review. *Int J Infect Dis*, 13: 125–33.
- Padayachy LC, Dattatraya M, 2018.** Hydatid disease (Echinococcus) of the central nervous system. *Childs Nerv Syst*, 34(10): 1967-71.
- Sadjjadi SM, Mikaeili F, Karamian M, Maraghi S, Sadjjadi FS, Shariat-Torbaghan S, Kia EB, 2013.** Evidence that the Echinococcus granulosus G6 genotype has an affinity for the brain in humans. *Int J Parasitol*, 43: 875-7.
- Sarkari B, Rezaei Z, 2015.** Immunodiagnosis of human hydatid disease: where do we stand? *World J Methodol*, 5: 185-95.
- Shafiei R, Teshnizi SH, Kalantar K, Gholami M, Mirzaee G, Mirzaee F, 2016.** The Seroprevalence of Human Cystic Echinococcosis in Iran: A Systematic Review and Meta-Analysis Study. *J Parasitol Res*, 1425147.
- Ullah R, Ullah I, Nazir M, Raza SS, Janan H, Khan N, Rukh Hijaz AS, Khan MB, Shah A, Bashir S, 2020.** Primary Hydatid Disease Of Chest Wall. *J Ayub Med Coll Abbottabad*, 32(3): 418-420.
- Wani NA, Kousar TL, Gojwari T, Robbani I, Singh M, Ramzan A, Khan Q, Kirmani A, Wani A, 2011.** Computed tomography findings in cerebral hydatid disease. *Turk Neurosurg*, 21(3):347–51.

Citation: Tuncer H, Parlak F, Çam B, Karaçam H, Coskun A, Akın B, Demirci B, 2023. A rare case of intracranial brain mass with an unexpected diagnosis: Hydatid cyst. *Biochem Biotechnol Res*, 11(1): 9-14.
