

External jugular vein thrombosis with pulmonary embolism: Case report

Dhafer JS Alhabbo

Department of Medicine, College of Medicine, University of Mosul, Mosul, Iraq.

Accepted 15 May, 2015

ABSTRACT

Pulmonary embolism (PE) is commonly presented with non-specific symptoms and clinical signs which are very easily missed or misdiagnosed. Massive PE may lead to death during the first few hours of the event. Therefore, early diagnosis and treatment is vital and very important because repeated embolization and death can be prevented with immediate treatment. Ken Moser explain the morbidity and mortality from these events as "substantial and unacceptable" as PE is not a disease by itself but it is rather a complication of deep vein thrombosis. Upper extremity deep venous thrombosis is not insignificant risk factor for PE. The objective of this study is to report pulmonary embolism secondary to external jugular vein thrombosis. The case report is a 45-year old male presented with history of dyspnea and right sided chest pain accompanied by tender right supraclavicular mass lesion. The patient was admitted to the intensive care unit in the teaching hospital. The diagnosis of external jugular vein thrombosis with secondary pulmonary embolism was made by C. T. angiography. In conclusion, external jugular vein thrombosis with secondary pulmonary embolism is rare but should be put in mind.

Keywords: Embolization, clinical signs, misdiagnosed, morbidity, mortality.

E-mail: dhaferalhabbo@yahoo.com. Tel: 009647701604355.

INTRODUCTION

Pulmonary embolism (PE) and deep venous thrombosis (DVT) incidence rises markedly in older age group and may be markedly increased in patients of >80 years (Silverstein et al., 1998).

Upper extremity deep venous thrombosis is less likely to lead to PE, on the other hand PEs more likely to originate from proximal DVT of the leg (Moser and LeMoine, 1981).

The external jugular vein contains one pair of valves at its point of entrance into the subclavian vein, and another pair at about four centimeters (one and a half inches) above this point; these valves do not stop reflux of blood back into the external jugular vein. The portion of the vein between the valves is dilated and called the sinus (Williams et al., 1989).

Upper extremity deep-vein thrombosis (UEDVT) is seen specially in patients treated by intravenous root by using indwelling catheter with increasing incidence of PE which may lead to increasing mortality and morbidities (Grant et al., 2012; Lee et al., 2012).

CASE REPORT

A 45-year old male was admitted to the haematology unit with a history of tender swelling in right supraclavicular region four to five weeks duration.

During his stay in the haematology unit, the patient develop right sided chest pain with dyspnea, during investigation they discovered high value of the D-dimer test and then referred to the Critical and Respiratory Care Unit on the 13/2/2012.

In the Critical and Respiratory Care Unit the patient gave history of two weeks dyspnea accompanied by cough with yellow sputum, haemoptysis and right sided pleuretic chest pain, with repeated attaches of pain of the right subcostal to right hypochondrial areas.

The patient is non-smoker, not alcoholic with no previous history of previous family or personal thrombotic events and on no specific daily drug therapy.

During examination of the patient in the Critical Respiratory and Care Unit, there was middle aged man

with mild dyspnea with a pulse rate of 100 bpm, temperature 38°C, respiratory rate of 20 breath pm, conscious and respond to commands.

Spo2 96 to 97%, auscultation of the chest revealed occasional rhonchi and crackles mostly in the right side mid to lower zone with diminished air entry in the lower base. During abdominal examination, there was mild tenderness in the right hypochondrium

Examination of right supraclavicular region revealed mild tender bead like lesions along the course of the external jugular vein.

Examination of the lower extremities was negative for clinical possibility of DVT.

The patient was diagnosed clinically as pulmonary embolism pending the result of the CT scan. We started him on full dose of heparin starting with 30000 unit/24 h intravenously according to body weight and then followed by Clexane (enoxaparin) 6000 bd in the fourth day pending the results of investigations, plus cephetriaxon 1 g intravenously twice daily.

RESULTS

RBC: $4.31 \times 10^{12}/L$ HCT 0. 27. HGB 75mm/ L, MCV: 64 fL,

MCH: 17.3 pg, MCHC: 270 g/L, RDW: 17.9 H%, MPV: $9.6 \mu m^3$, PDW 13.8%

WBC: $10.9 \times 10^9/L$, PLT: $273 \times 10^9/L$, PCT: 262%, ESR: 38 mm/H

Blood film indicates normochromic normocytic anaemia.

D. Dimer test: >500,

Serum potassium: 4.1 mmol/L, Serum calcium (ionized): 1.14 mmol/L,

Serum Bilirubin: 17 $\mu mol/L$, Serum alkaline phosph: 36 U/L

S.A.S.T: 31U/L Serum Protein: 63 g/L, and Albumine:40 g/L.

Fasting blood sugar: 6.0 mmol/L

Blood urea: 5.2 mmol/L

General urine examination: Normal.

HBS-Ag; Negative and HB Core-IgM; Negative for HCV.

Latex Fixation; negative, C. reactive protein; positive and con.C.R.P; 96 g/L.

Lung function test; mild restrictive ventalitary defect.

ECG sinus tachycardia. Echocardiography; hypokinesia of anteroseptal area of the cardiac wall.

Records of the ultrasound of thyroid and abdomen were normal.

Venous Doppler Ultrasonography – colour Doppler of the right external jugular vein; established the diagnosis of dilated and tortuous vein with thrombosis of the external jugular vein up to the angle of the right jaw as in Figures 1 to 4.

Venous Doppler Ultrasonography – colour doppler of the lower extremities were normal.

C.T.Angiography of pulmonary vessels established the

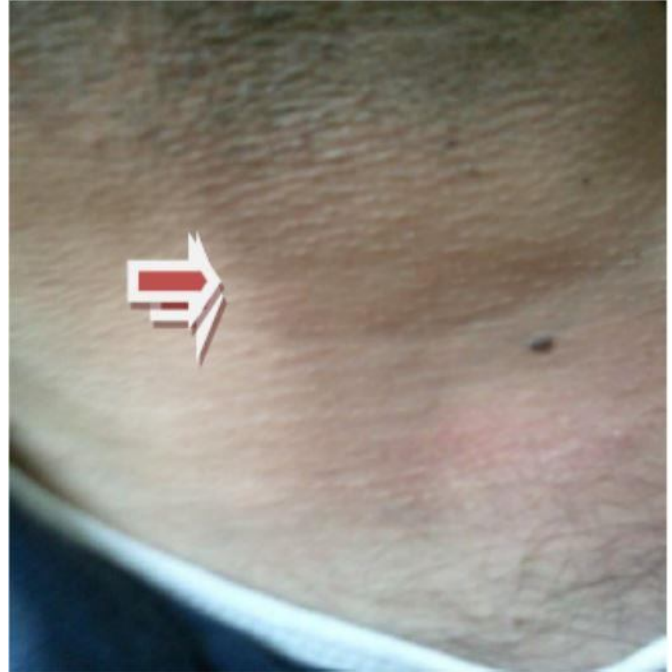

Figure 1. Picture of patient's neck.

diagnosis of big thrombus involving the right pulmonary artery and its branches with pulmonary infarction in the right lower lobe of the lung with pleural effusion as seen in Figures 4 to 7.

The patient was put on Clexane (enoxaparin) 6000 bd and then started on 5 mg warfarin on day five after the diagnosis was settled as pulmonary embolism.

The warfarin dose of 5 mg/day continued till day three were prothrombine time was done and it was (patient = 25, control = 12.5 and INR = 3.0) then heparin stopped and warfarin continued and to be followed by regular INR study. The patient was discharged after he made a good recovery and was stable.

DISCUSSION

Possible risk factors for upper extremity deep venous thrombosis UEDVT include trauma, superior vena cava obstruction syndrome, and hypercoagulable states such as central venous catheters inserted for chemotherapy or parenteral nutrition, and cancer. Furthermore, it is a rare clinical entity which makes up approximately 4% of all episodes of deep venous thrombosis (Blom et al., 2005; Joffe and Goldhaber, 2002).

In our patient, there were none of the above mentioned diseases, no history of central venous catheter insertion and there was no convincing evidence of hypercoagulable state. Anyhow factor V Leiden is a strong risk factor for deep vein thrombosis, but not as strong a risk factor for pulmonary embolism, the

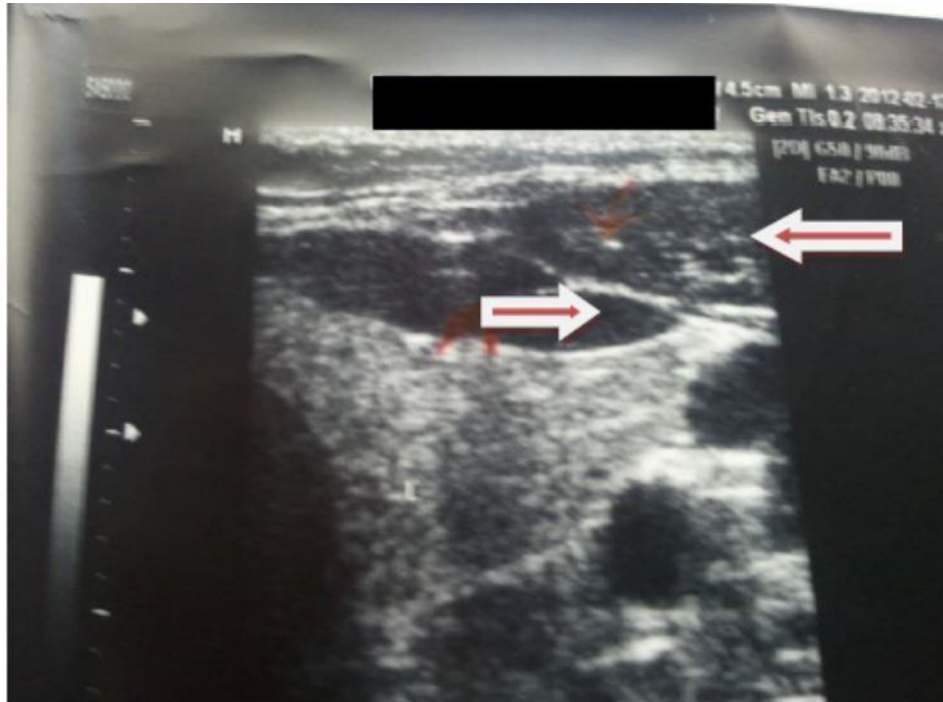


Figure 2. Venous doppler ultrasound picture of the external jugular vein.

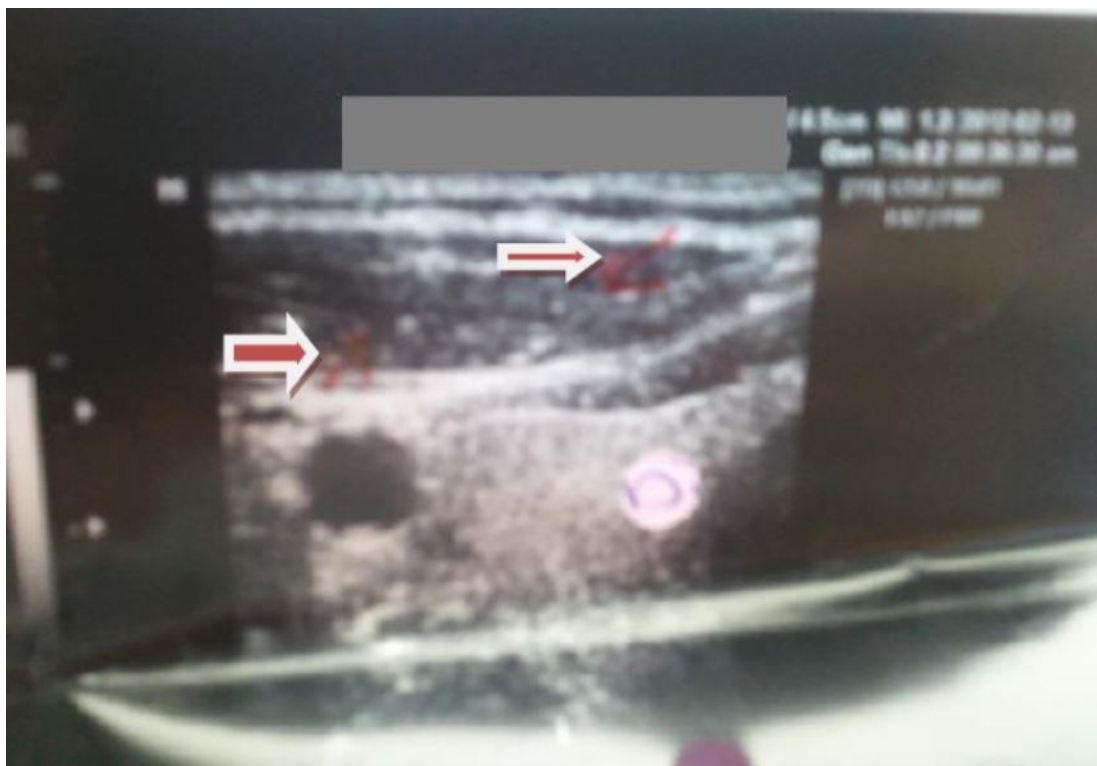


Figure 3. Venous doppler ultrasound picture of the external jugular vein.

prevalence of factor V Leiden among patients with fatal pulmonary embolism in autopsic studies was not different

from that of the general population (Vandenbroucke et al., 1998). Increased thrombin formation may impair

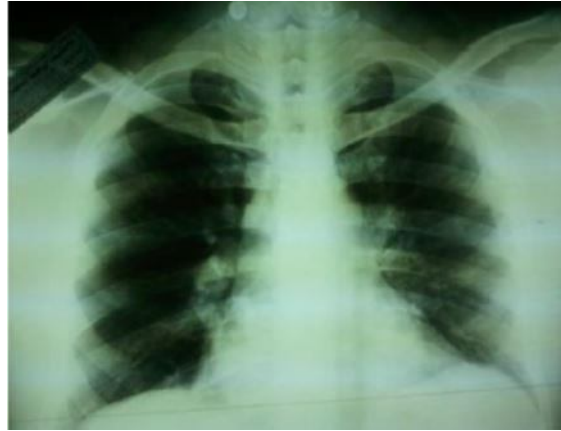

Figure 4. Chest x-ray of the patient.

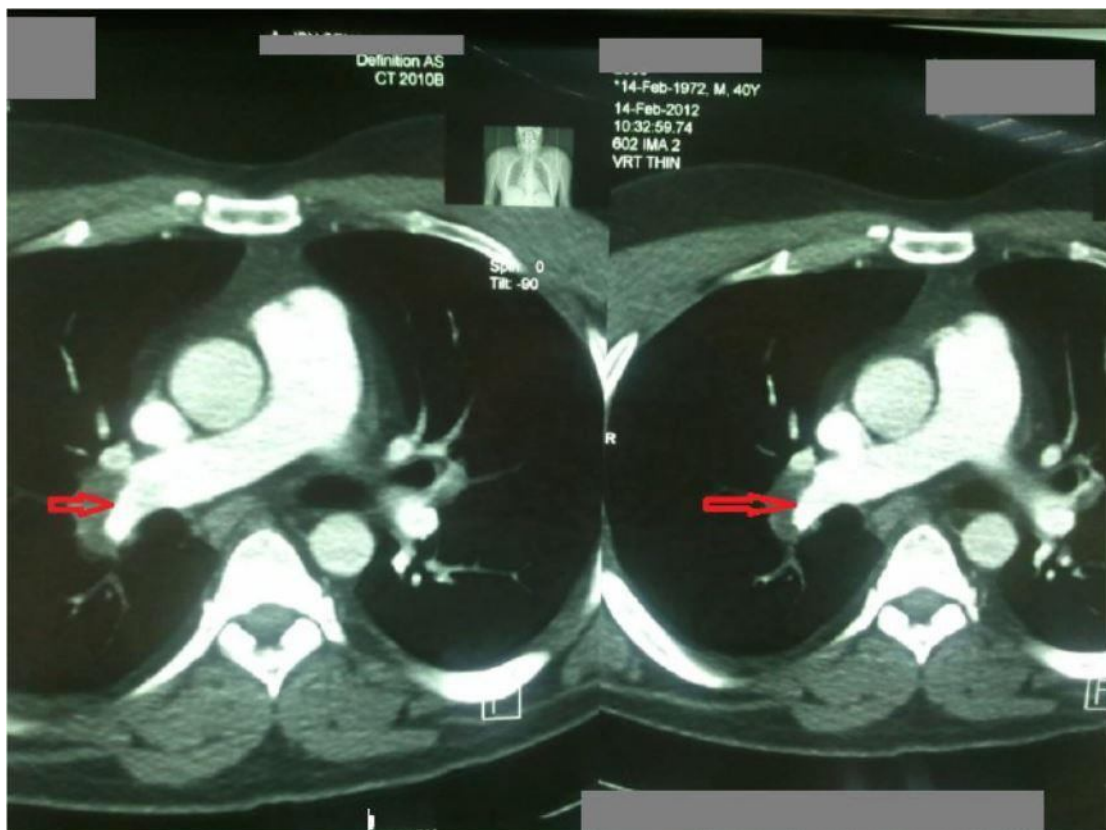

Figure 5. CT angiography of the patient in the intensive care unit.

fibrinolytic response through activation of thrombin activable fibrinolysis inhibitor, a mechanism shown to exist *in vitro* in the presence of factor V Leiden (Bajzar et al., 1996).

Accordingly, we can say that although the test for factor V Leiden is commonly not available for our lab and patients, it is less likely that our patients has factor V Leiden abnormality.

Phlebectasia of the lower part of the internal jugular vein first reported in 1875, involving the neck veins including anterior and external jugular veins in children have been reported in the world literature (Paleri and Gopalakrishnen, 2001; Sander et al., 1999).

This finding does not apply to my patient because he is beyond childhood period as he is a 45-year old male.

Bilateral externaljugular veinthrombosis of

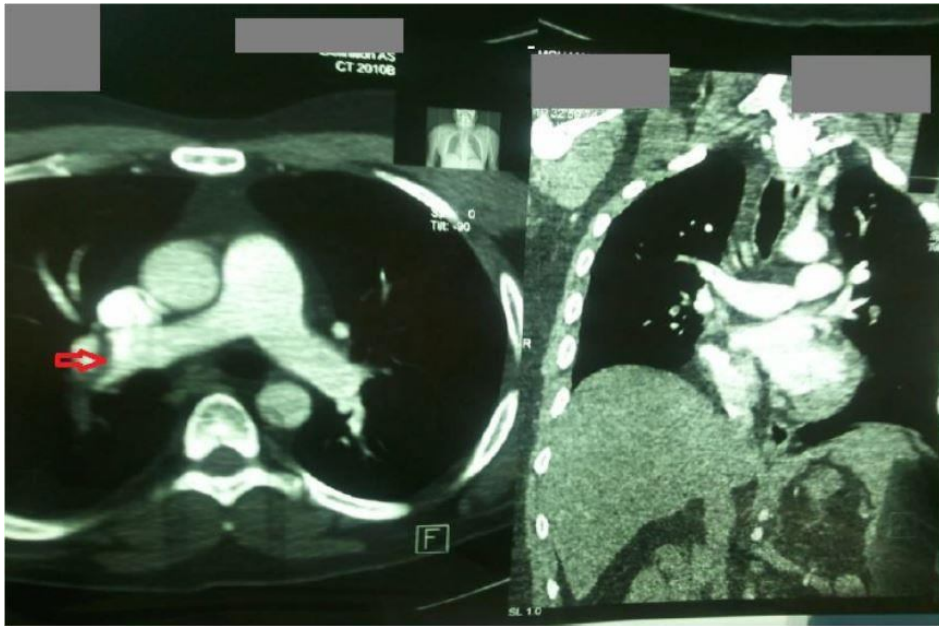


Figure 6. CT angiography different view of the patient in the intensive care unit.

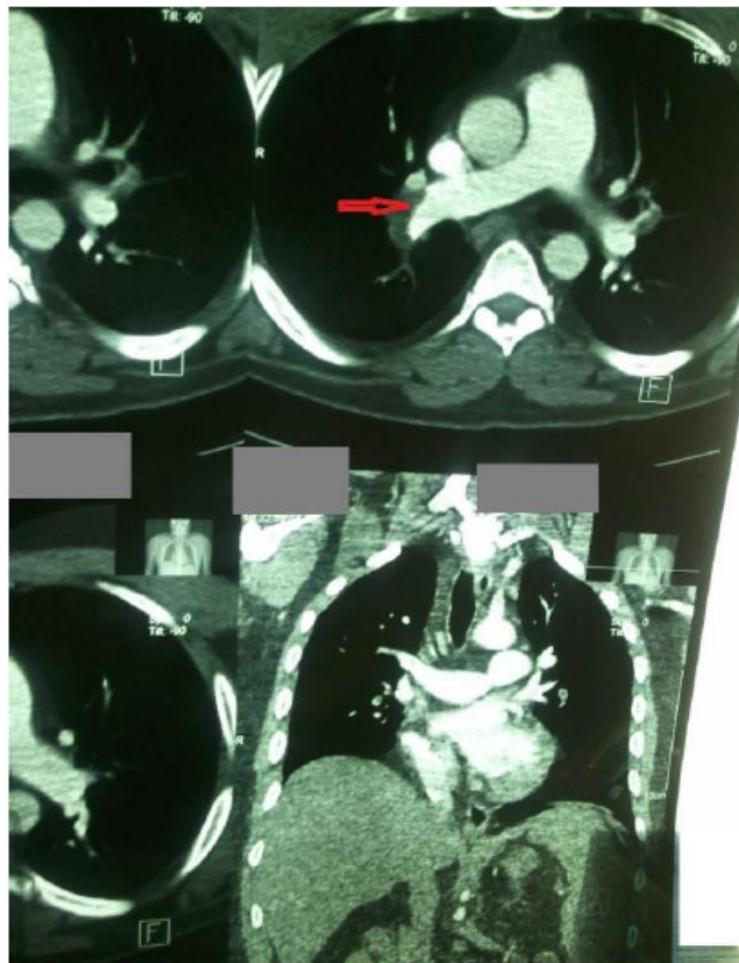


Figure 7. CT angiography another different view of the patient in the intensive care unit.

undetermined etiology was reported but without PE (Sengupta et al., 2001; Quinn et al., 1996).

This is different from our patient as he was suffering from PE as the most important illness with external jugular vein thrombosis.

Bacterial infection with thrombophlebitis as Lemierre's disease, caused by fusobacterium necrophorum, manifests as pharyngitis, jugular venous thrombosis and septic pulmonary embolism in young adult was reported since 1900 (Edlibam et al., 2000).

However, our patient does not suffer from thrombophlebitis neither has features suggestive of Lemierre's disease.

Pulmonary embolism can occur even secondary to very awkward and remote venous thrombosis e.g. spermatic vein thrombosis (Castillo et al., 2008).

However, previous reports found that the incidence rate of PE and mortality rate from UEDVT were not insignificant at 9 and 6%, respectively (Grant et al., 2012; Lee et al., 2012).

From the above review of literatures, we can say according to my humble knowledge, that our patient could be the first case report of external jugular vein thrombosis complicated by pulmonary embolism in Iraq.

In conclusion, external jugular vein thrombosis exists and should be looked for especially in patient with pulmonary embolism of unknown etiology.

Learning points

1. In summary this topic is important and as far as I know it is the first time report of PE secondary to external jugular vein thrombosis.
2. External jugular vein thrombosis can cause PE.
3. The key findings were right side external jugular vein thrombosis with PE.
4. The early diagnosis of PE was vital in preventing death in such 45 year old man.

REFERENCES

- Bajzar** L, Kalafatis M, Simioni P, Tracy PB, **1996**. An antifibrinolytic mechanism describing the prothrombotic effect associated with factor V Leiden. *J Biol Chem*, 271:22949-22952.
- Blom** JW, Doggen CJ, Osanto S, Rosendaal FR, **2005**. Old and new risk factors for upper extremity deep venous thrombosis. *J Thromb Haemost*, 3:2471-2478.
- Castillo** OA, Diaz M, Vitagliano GJ, Metrebian E, **2008**. Pulmonary thromboembolism secondary to left spermatic vein thrombosis. *Urol Int*, 80:217-218.
- Edlibam** C, Gharbi R, Weekes JWN, **2000**. Septic jugular thrombophlebitis and pulmonary embolism: A case report critical care and resuscitation. 2:38-41.
- Grant** JD, Stevens SM, Woller SC, Lee EW, Kee ST, Liu DM, Lohan DG, Elliott CG, **2012**. Diagnosis and management of upper extremity deep-vein thrombosis in adults. *Thromb Haemost*. 108(6):1097-1108.
- Joffe** H, **Goldhaber** S, **2002**. Upper-extremity deep vein thrombosis. *Circulation*, 106:1874-1880.
- Lee** JA, Zierler BK, Zierler RE, **2012**. The risk factors and clinical outcomes of upper extremity deep vein thrombosis. *Vasc Endovascular Surg*, 46(2):139-144.
- Moser** KM, **LeMoine** JR, **1981**. Is embolic risk conditioned by location of deep venous thrombosis? *Ann Intern Med*; 94(4 pt 1):439-444.
- Paleri** V, **Gopalakrishnen** S, **2001**. Jugular phlebectasia: Theory of pathogenesis and review of literature. *Int J Pediatr Otorhinolaryngol*, 57:155-159.
- Quinn** SJ, Bleach NR, Ong PS, Mackay IS, **1996**. Thrombosed jugular vein presenting as a hard neck mass. *J Laryngol Otol*, 110(2):179-181.
- Sander** S, Elicevik M, Ural M, Vural O, **1999**. Jugular phlebectasia in children: is it rare or ignored? *J Pediatr Surg*, 34:1829-1832.
- Sengupta** S, Kalkonde Y, Khot R, Paithankar M, Salkar R, Salkar H, **2001**. Idiopathic bilateral external jugular vein thrombosis: a case report. *Angiology*, 52(1):69-71.
- Silverstein** MD, Heit JA, Mohr DN, Petterson TM, O'Fallon WM, Melton LJ, **1998**. Trends in the incidence of deep vein thrombosis and pulmonary embolism: A 25-year population-based study. *Arch Intern Med*; 158:585-593.
- Vandenbroucke** JP, Bertina RM, Holmes ZR, Spaargaren C, van Krieken JH, Manten B, Reitsma PH, **1998**. Factor V Leiden and fatal pulmonary embolism. *Thromb Haemost*; 79:511-516.
- Williams** PL, Warwick R, Dyson M, Bannister LH, **1989**. *Gray's Anatomy*. 37th edn. Edinburgh: Churchill Livingstone.

Citation: Alhabbo DJS, 2015. External jugular vein thrombosis with pulmonary embolism: Case report. *Int Res J Med Med Sci*, 3(4): 116-121.
