

# Differential diagnosis of focal hepatic lesions using ultrasound confirmed with histopathology

Rania Mohammed Ahmed\*, Sharifah Alkathiri, Waad Altalhi, Hatun Eid, Manar Alshalwai and Sara Alotaibi

Department of Radiological Sciences, College of Applied Medical Sciences, Taif University, Taif, KSA.

Accepted 8 April, 2020

---

## ABSTRACT

Advances in imaging technology over the past decades have contributed to better characterization of hepatic lesions. This study aims to differentiate focal hepatic lesions from their ultrasound (U/S) features and compared the obtained results with histopathology. A descriptive retrospective study of 100 patients who had focal hepatic lesions were reviewed during the period from 2012 to 2019 at King Abdul-Aziz Specialist Hospital, Taif, KSA. The inclusion criteria were Adults Saudi patients, ages 18 and above. LG-9 and Philips ultrasound machines with 3.5 MHz transducers were used in this study. Age group (55 to 80 years) represented 44%, mean age was 49 years, 92% were married. Regarding shape of the lesions during U/S scan, 47% of irregular outline were malignant ( $p=0.00$ ), 93% of the rounded lesions were benign ( $p=0.00$ ), 86% of well-defined lesions margins were benign in histopathology, 61% ill-defined margin lesions were malignant and 73% of hyperechoic lesions were hemangioma ( $p=0.02$ ). Regarding nature of hepatic lesions during U/S, 87% of solid lesions were malignant ( $p=0.03$ ), while 89% of cystic lesions were benign. 61% of hypoechoic lesions were malignant. 80% from vascular lesions under color Doppler were benign. U/S sensitivity and specificity were 93.5 and 98%, respectively. U/S is a useful tool in differentiation cystic hepatic lesions from solid ( $p=0.03$ ). Comparable studies with large samples must be done in Taif region to provide data base for hepatic lesions.

**Keywords:** Ultrasound, liver, lesions, benign, malignancy, histopathology.

---

\*Corresponding author. E-mail: rania\_awad1@hotmail.com.

---

## INTRODUCTION

Advances in imaging technology over the past decades have contributed to better characterization of hepatic lesions to a wide range of diagnostic chances. Smit (2017) found that focal hepatic lesions are divided into benign and malignant. Most benign liver lesions, such as focal nodular hyperplasia (FNH), cysts, hemangiomas and hamartomas, do not require treatment after coincidental finding during conventional diagnostics; also, malignant lesions in the liver can be divided into primary and secondary tumors. Primary malignant tumors, in the case of cholangiocarcinoma or hepatocellular carcinoma (HCC) in a non-cirrhotic liver, are often detected in an advanced stage after diagnosis with nonspecific abdominal complaints.

Van Cutsem et al. (2014) and Kemeny and Fata (1999) reported that malignant lesions in the liver are divided into primary and secondary tumors. Primary malignant masses, such as cholangiocarcinoma or hepatocellular carcinoma (HCC) are often detected in an advanced stage after the diagnosis with nonspecific abdominal complaints. Colorectal metastases are considered the largest group of secondary tumors in the liver where 30 to 50% of patients diagnosed with primary colorectal cancer suffer from metastases at some stage. Generally, liver metastases are other common sites of primary malignancy are gastrointestinal tract, breast, lung, urogenital tract and skin.

Parkin et al. (1999) reported that each year, 50000 to 1

million individuals are diagnosed with hepatic lesions worldwide. Bolandi (1992) has stated that the most common primary liver cancer comprises of 80% of primary liver malignancies. It is typically a disease of middle aged and elderly individuals, and had variable sonographic appearance. The masses may be hypoechoic, complex or echogenic. Most small (<5 cm) HCC are hypoechoic and regarding ultrasound (U/S) appearance of hepatic lesions, also reported that a thin peripheral hypoechoic halo, which corresponds to a fibrous capsule, is seen most often in small HCC during U/S scan. With time and increasing size, the masses tend to become more complex in nature and heterogeneous echotexture as a result of necrosis and fibrosis. Calcification is uncommon. Small tumors may appear diffusely hyperechoic (Gerstenmaier and Gibson, 2014). Brunt (2000) reported that liver ultrasound scan, which is non-invasive, nonionizing, cost effective and time conserving, is the most sensitive screening tool for sorting out the organ involved in patients with abdominal symptoms and non-invasive approaches for assessment of liver histology include routine laboratory tests like serum markers, liver functions test, and radiological evaluation of liver. Liver histological diagnosis based on needle biopsy determines the inflammatory activity (grading), the extent of fibrosis (staging), and other comorbidities.

Torzilli et al. (2004) stated that diagnostic tools commonly used include the serum tumor marker Alfa-fetoprotein (AFP), radiographic imaging, and fine needle aspiration liver cytology and or biopsy (FNAC & FNAB). No universal guidelines for diagnosis exist, partly as a result of marked differences in the diagnostic approach between Eastern and Western institutions.

## Objectives

This study aims to:

- Find out the most commonly affected age group in the population treated at the King Abdul-Aziz Specialist Hospital.
- Differentiate between malignant and benign focal hepatic lesions from their ultrasound characteristics features and the correlate ultrasound findings of focal hepatic lesions with fine needle aspiration cytology or biopsy results (histopathology).

## SUBJECTS AND METHODS

### Setting and research design

This is a retrospective study performed by reviewing all patients' medical records in the period from September 2012 to March 2019 at King Abdul-Aziz Specialist Hospital (KAASH), Taif city, Saudi

Arabia.

### Study population

Data was collected from records of Saudi patients living at Taif region with the age ranged 18 to 80 years old who attended ultrasound department for the evaluation of their hepatic lesions. All ultrasound images were obtained via gray scale and color Doppler. Then, ultrasound results of suspicious hepatic lesions were confirmed with their histopathology results.

**Inclusion criteria:** Adults Saudi patients, ages 18 and above.

**Exclusion criteria:** Uncompleted patients records.

### Tool of data collection

A structured checklist was designed specifically for data collection of this study by the researchers based up on review of literature; the checklist consists of three parts:

**First part:** Socio-demographic data (age, gender, marital status, family history and habits (smoking)).

**Second part:** Ultrasound scan results which included information regarding the four features of the liver lesion; shape (rounded, oval or irregular outline), margins (ill-defined – well-defined), width: antero-posterior (AP) ratio ( $\leq 1.5$ , 1.5 to 4 cm or  $\geq 4$  cm) and echogenicity (hyperechoic, hypoechoic or iso-echoic). Also, this part contained Doppler flow results (vascular – a vascular) and type of vascularity (peripheral flow or central flow).

### Third part: Histopathology results

The diagnoses and categorization of hepatic lesions into benign, malignant, on indeterminate were made based on the ultrasound features and confirmed by fine needle aspiration cytology/biopsy (FNAC/FNAB) or histopathology.

U/S features that most reliably characterize masses as benign are: a round or oval shape, circumscribed margins, and a width to AP dimension ratio greater than 1.4 cm. Features that characterize masses as malignant include irregular shape, micro-lobulation, and width-to-AP dimension ratio of 1.4 or less. A few gently curving, circumscribed lobulation (macro-lobulation) are considered as benign features, whereas many small lobulation of 1 to 2 mm (micro-lobulation) are considered a malignant characteristic in a recent study.

### Patient preparation

From the records, all patients were prepared as follow: fasting for at least 6 to 8 hours before the examination. Patients were laid supine on the examining table, and the radiologist used a warm water-based gel over the area of interest that helps the transducer to contact with the skin and the ultrasound images were obtained.

### U/S technique and color Doppler protocol

U/S frequency transducer range between 3.5 and 5 MHz, for adults use 3.5 MHz And for thin adults and a 5 MHz transducer was used according to the hospital protocol.

All patients were examined with LG-9 and Philips ultrasound machines equipped with a 3.5 to 5.0-MHz probe. Scans were obtained along multiple sagittal, transverse oblique, subcostal, intercostal and coronal planes and in both oblique and decubitus

views as necessary to demonstrate the lesion clearly. Color Doppler and power Doppler examinations were performed using optimized color Doppler parameters. The power level, threshold, persistence, and wall filter were individually adjusted to maximize the detection of blood flow with the field of view. Taking into account descriptive reports, photographs, and hard copies, the gray scale and color and power Doppler sonographic images were interpreted by the consensus of 2 sonographers. The reviewed items included lesion size, lesion number (solitary or multiple), appearance of the lesion margin, and lesion shape (regular or irregular). Color Doppler characteristics reviewed included flow patterns (arterial or venous wave), location of flow signal, and systolic velocity. The percentages of sonographic features found within each category of disease were calculated as reported in study by Liang et al. (2005).

Various sonographic features of focal liver lesions were observed, which include location within liver (right lobe, left lobe, both lobes), shape, margin, AP ratio and sonographic echogenicity (hyperechoic, hypoechoic, anechoic or mixed echogenic).

### Histopathology protocol

Patients with suspicious hepatic lesions underwent biopsy by percutaneous using a 14 gauge needle coupled with a semi-automatic core biopsy gun or vacuum-assisted liver biopsy using an 11 gauge needle. It was performed by well-trained pathologists, using vigorous sampling and ultrasound guide form palpable or hardly palpable lesions to determine whether the use of cell block improves diagnostic accuracy of FNAB, then compared the cytology diagnosis and the one performed on cell block section. In cases of simple cysts and galactoceles, no histopathology confirmation was done. Aspiration of cyst was done to confirm. The procedure is a safe, economical, effective, and accurate technique. Samples were carried out by the histopathologist experienced in the diagnosis of liver lesions. Malignant lesions were classified into seven categories according to histology: (a) invasive ductal carcinomas not otherwise specified, medullary, apocrine, neuroendocrine carcinoma (b) tubular, mucinous, papillary carcinoma, cribriform carcinoma (c) metaplastic, anaplastic, undifferentiated high grade carcinoma (d) invasive lobular carcinoma (e) mixed ductal and lobular carcinoma; (f) in situ carcinoma and (g) metastatic carcinoma.

### Fine-needle aspiration cytology/biopsy (FNAC/B)

Fine-needle aspiration cytology/biopsy (FNAC/B) of the liver is a well-established method to obtain fluid/tissue fragments and smears for preoperative diagnosis of liver lesions. FNAB is actually a safe and low-cost procedure that can avoid unnecessary surgery, differentiating with high accuracy benign and malignant lesions.

### Data analysis

The software Statistical Package for Social Sciences (SPSS) 20.0 was used to analyze the data. Pearson's correlation and Chi-square tests were used for statistical analysis of the associations between the study variables. The statistical association was considered to be significant when  $P \leq 0.05$ .

### Ethical considerations

Formal approvals (No: 129) from ethics committee of health affairs in Taif city and from KAASH were obtained prior to conduct this study. Ethical committee in KAASH was assured that the data of

this research was not be reused without second permission. No personal information of any patient will be published.

## RESULTS

After reviewing the records of the patients with the focal hepatic lesions who underwent ultrasound scan then followed by histopathology to categorize the hepatic lesions, there were 100 patients included in this study, 54% were male and 46% were female, with an age range of 18 to 80 years, and mean age of 49 years. The age group 55 to 80 years was the highly affected group by hepatic lesions with 44% followed by the age group 35 to 54 and 18 to 34 years old with 39 and 17%, respectively. Table 1 summarizes the age frequency among study sample. There was a significant statistical association of the lesion type with age ( $p = 0.09$ ), as shown in Table 2.

Regarding site of hepatic lesions according to U/S; (50%) of the focal hepatic lesions were found in the right lobe of the liver, as shown in Figure 1, also the current study revealed strong statistical correlation between site of hepatic lesions and lesion type ( $p = .03$ ), as in Table 3.

The lesions means sizes were  $1.5 \pm 4.0$  cm for both hepatic lobes. A Pearson's correlation between lesions size and sample ages revealed a significant statistical association ( $p = 0.005$ ), as shown in Table 4.

Table 5 presents the U/S features of the detected hepatic lesions and correlations between the U/S features and histopathology results. From 100 focal hepatic lesions: 69% were benign and 31% were malignant, as shown in Figure 2; out of 73 solid lesions there were 87.1% malignant lesions, 17 were complex and 10 were cystic hepatic lesion; (89%) of them were benign, with a significant statistical correlation ( $p = .03$ ).

Regarding lesions echogenicity there were 44 hyperechogenic lesions, followed by 21 heterogeneous echotexture lesions and 18 hypoechogenic lesions, 16 echo free lesions and 1 lesion was isoechoic. All the malignant lesions matched the suspicious U/S features, and among 18 hepatic lesions, 11 (61%) lesions showed hypo echogenic echotexture and 7 (33%) were heterogenous echotexture. All suspicious U/S features were statistically associated with the histopathology results ( $p < 0.03$ ), and among 58 irregular out lines lesions, where 27 (47%) were malignant, while 38 (93%) from the rounded lesions were benign. Regarding lesions margins on U/S, among 36 ill-define lesions 22 (61%) were malignant and out of 64 well-define lesions on U/S there were 55 (86%) benign and only 9 (14%) from well-define lesions were malignant. Out of 26 malignant lesions there were 12(46%) measured  $\geq 4$ cm. Regarding color Doppler, 47 (80%) of a vascular lesions were benign, while 10 (46%) of the malignant lesions had peripheral flow. All suspicious U/S features were statistically associated with histopathology results ( $P =$

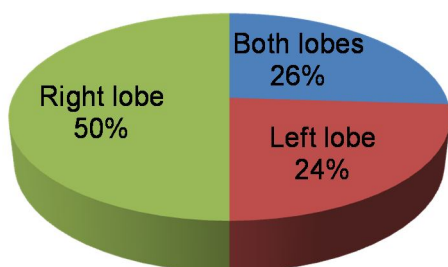
**Table 1.** Frequency of study sample age (n = 100).

Age groups	Frequency	%
18-34	17	17.0
35-54	39	39.0
55-80	44	44.0
Total	100	100.0

**Table 2.** Correlation of age with histopathology result (n = 100).

Age groups	Histopathology result		Total	Approx. Sig.
	Benign	Malignant		
18-34	15	2	17	.09
35-55	32	7	39	
Over 55	31	13	44	
Total	78	22	100	

### Site of the lesions

**Figure 1.** Frequency of hepatic lesions among liver lobes (n = 100).

0.00, 0.00, 0.02 and 0.005, respectively.

Regarding lesions types according to histopathology

**Table 3.** Correlation of hepatic lesions sites with lesions types (n = 100).

Site of hepatic lesions according to U/S	Lesions types according to histopathology							Total	Asymp. Sig. (2-sided)
	Adeno-carcinoma	HCC	Lymphoma	Mets	Hemangioma	Cyst	Abscess		
Left lobe	1	1	1	5	9	7	0	24	
Right lobe	2	8	0	2	24	9	5	50	
Both lobes	1	2	1	5	12	1	4	26	.03
Total	4	11	2	12	45	17	9	100	

The right (Rt) lobe of the liver was affected in 50% of cases in our study and this finding agrees with Hima et al.

results of the suspicious hepatic lesions on the U/S, there were 45 hemangiomas, 11 HCC, 17 cystic lesions, 12 metastasis lesions and 9 abscess, 4 adenocarcinoma and 1 cystic lesion. 73% of hyperechoic lesions were confirmed as hemangioma, 67% of hypoechoic lesions confirmed as malignant lesions with histopathology and 33% of heterogeneous lesions were confirmed to be HCC with histopathology and 100% of isoechoic lesion confirmed as mets lesions; there are a significant statistical correlations between U/S findings and histopathology results ( $p=0.00$ ,  $0.00$  and  $0.06$  respectively, as shown in Table 6.

The histopathology results are taken as gold standard in comparing and coordinating the diagnosis made by U/S, the U/S characterized 29 lesions out of 31 to be malignant and 1 lesion as benign cyst was confirmed as malignant cystic lesion with histopathology with sensitivity and specificity were 93.5 and 98.6%, respectively.

### DISCUSSION

Advances in imaging technology over the past decades have contributed to better characterization of hepatic lesions. The current study showed sample age ranged from 18 to 80 years old, 54% of them were male and 46% were female, with ratio of 1.2:1 and mean age was 49 years. The age group 55 to 80 years was the highly affected group by hepatic lesions with 44%, followed by the age group 35 to 54 years old with 39%; these results are in agreement with Hima et al. (2014) who reported that males were predominantly affected by focal and diffuse hepatic lesions than females with mean age of 42.5 years and male to female ratio of 1.6:1 and primary malignant tumors, metastasis, abscess have highest incidence in the age group of 41 to 50 years. Also our study agree with Ferenci et al. (2010), who stated that males at greater risk for hepatic malignancy than females.

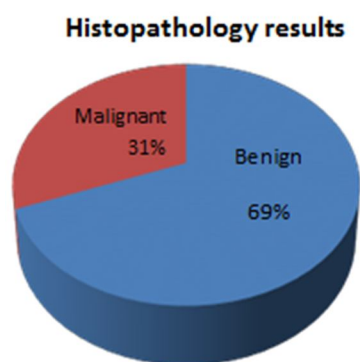
(2014) who found that 63 cases (64.28%) of hepatic lesions in their study sample were in right lobe and 15

**Table 4.** Correlation of age with lesion width (n = 100).

Age groups	Lesion width on U/S			Total	Asymp. Sig. (2-sided)	Approx. Sig.
	≤1.5 cm	1.5-4 cm	≥4cm			
18-34	10	3	4	17	.001	.005
35-55	7	26	6	39	.001	
Over 55	7	21	16	44	.005	
Total	24	50	26	100		

**Table 5.** Correlation of U/S features with histopathology results (n = 100).

U/S features of hepatic lesions		Histopathology results		Total	Exact sig.
		Benign (%)	Malignant (%)		
Nature of the lesions	Cystic	15 (89)	2 (11)	17	0.031
	Solid	46 (63)	27 (37)	73	
	Complex	8 (80)	2 (20)	10	
Lesions echogenicity	Hyperechogenic	33 (75)	11 (25)	44	0.030
	Hypoechoic	7 (39)	11 (61)	18	
	Iso-echoic	0	1 (100)	1	
	An echoic	15 (94)	1 (6)	16	
	Heterogeneous echotexture	14 (67)	7 (33)	21	
Shape of the lesions	Round	38 (93)	3 (7)	41	0.00
	Oval	0	1 (100)	1	
	Irregular outlines	31 (53)	27 (47)	58	
Margin of the lesions	Well-defined	55 (86)	9 (14)	64	0.000
	Ill-defined	14 (39)	22 (61)	36	
Width: AP ratio of the lesions	≤1.5 cm	21 (84)	4 (16)	25	0.020
	1.5-4 cm	34 (69)	15 (31)	49	
	≥4cm	14 (54)	12 (46)	26	
Doppler flow under box of color Doppler	A vascular	47 (80)	12 (20)	59	0.005
	Central	9 (50)	9 (50)	18	
	Peripheral	13 (57)	10 (43)	23	



**Figure 2.** Histopathology results of hepatic lesions (n = 100).

cases (15.1%) on left lobe; also, this study is in

agreements with Ranjan and Singh (2017) and Thimmaiah (2014) who reported that right lobe was involved in 56 and 80%, respectively.

The current study findings showed 100 hepatic lesions, where 73 lesions were solid, 17 were complex nodules, and 10 were cystic lesions on U/S, and according to histopathology results of the suspicious hepatic lesions on the U/S, there were 69 benign lesions, 45 (65.1%) of them were hemangiomas followed by 17 (24.6%) cystic lesions, 9 (13%) abscess and among 31 malignant lesions; there were 11 (35.5%) HCC, 12 (38.7%) metastasis lesions and 4 (12.9%) adenocarcinomas, with p=0.00. These findings are in agreement with Hima et al.

**Table 6.** Correlation of U/S echogenicity of hepatic lesions with Histopathology results (n = 100).

U/S echogenicity of the lesions during U/S	Histopathology results								Total	Asymp. Sig. (2-sided)
	Adeno-carcinoma	HCC	Lymphoma	Metastases	Malignant cystic lesions	Hemangioma	Cyst	Abscess		
Hyperechoic	2	2	0	7	0	33	0	0	44	.000
Hypoechoic	1	4	2	3	1	6	0	1	18	.000
Isoechoic	0	0	0	1	0	0	0	0	1	.026
An echoic	0	0	0	0	0	0	16	0	16	
Heterogeneous	1	5	0	1	0	6	0	8	21	
Total	4	11	2	12	1	45	16	9	100	

(2014) who reported that there is significant association between USG findings and FNAC findings ( $p < 0.001$ ).

U/S features of the detected hepatic lesions and correlations between the U/S features and histopathology results in this study, 87.1% of the solid lesions were malignant, 89% of cystic lesions were benign. Also, it showed that 33 (73.4%) of hemangiomas were hyperechoic, 6 (13.3%) were isoechoic and 6 (13.3%) were hypoechoic on U/S; these findings are in agreement with Hapani et al. (2014) who reported that a minority of hemangioma may present as an isoechoic or hypoechoic mass relative to the liver parenchyma. Also our study is in agreement with Ferenci et al. (2010) who found that hepatic cavernous hemangiomas are the most common benign tumors of the liver.

Regarding the shape of lesions on U/S in current study, findings showed that (47%) of irregular out lines lesions were malignant, while 93% of rounded lesions were benign hepatic lesions, 86% of well-defined margins lesions were benign in histopathology results, while 61% of ill-defined lesions were malignant.

Regarding lesions echogenicity on U/S in this

study, majority i.e. 44 hyperechogenic lesions, out of these 75% were benign, followed by 21 heterogeneous echotexture lesions and 18 hypoechoic lesions, out of these 61% were malignant, among 58 irregular out lines lesions 47% of them were malignant, while 93% from the rounded lesions were benign.

Current study showed that 45.5% of HCC were hypoechoic lesions, while 36.4% were heterogeneous echotexture lesions, and among 36 ill-define lesions 22 (61%) of ill-define lesions were malignant and out of 64 well-define lesions on U/S there were 55 (86%) benign; these findings agree with McClune and Tong (2010) who reported that HCC appears as small hypo-echoic lesion with poorly defined margins and coarse irregular internal echoes. When the tumor grows, it can sometimes appear heterogeneous. Also, it agrees with Mobarak et al. (2015) who stated that HCC appears as small hypo-echoic lesion with poorly defined margins and coarse irregular internal echoes, and with Kemp et al. (2013) who stated that some hepatic lesions may show bizarre sonographic appearance like irregular echogenicity, interspersed with disorganized low level echoes or hypoechoic.

This study showed that 80% of a vascular lesions were benign, while 10 (46%) of the malignant lesions had peripheral flow. All suspicious U/S features were statistically associated with histopathology results ( $p = 0.005$ ).

Liang et al. (2005) and Sinan et al. (2002) concluded that ultrasonography when adopted as an initial imaging modality was seen as a method which reduced the cost and time to arrive at a diagnosis. Regarding the sensitivity and specificity of U/S in diagnosing lesions malignancy in this study, accurate characterization of hepatic lesions by U/S in relation to histopathology was done in 31 focal hepatic lesions, 29 from them were confirmed as malignant lesions as suspected by ultrasound, with sensitivity of 93.5%, and false negative diagnosis in two cases which appear in U/S as benign cystic lesions while the histopathology results diagnosed them as malignant with overall specificity of 98.6%.

High degree of sensitivity and specificity of ultrasound diagnosis in the present study confirms the value of sonographic evaluation of focal liver lesions, and these findings are in agreement with Hima et al. (2014), who reported sensitivity of 84.6% and specificity of 93%, and with McClune

and Tong (2010) who reported that U/S specificity were (97%), and also in agreement with Thimmaiah (2014) who stated U/S sensitivity in the diagnosis of focal liver lesions between 91 and 95% with a specificity of 92 to 100%, respectively; also Yang et al. (1986) reported ultrasonography sensitivity of 92.3% and specificity of 98.3%.

## Conclusion

This study concluded that solid hepatic lesions are the most common type of lesions, also study revealed that age is represented a serious risk factor for malignancy in the liver; all the study sample which had malignant focal hepatic lesions aged 55 to 80 years old. Most of selected hepatic lesions with suspicious features were confirmed as malignant in histopathology with high degree of sensitivity and specificity. However, suspicious features on U/S were hypoechoic, ill-defined margins and irregular outlines. Thus, both sonographic features and histopathology results confirmation are important in hepatic lesions diagnosis, oval shape lesions with well-defined margins such as cyst and hemangiomas with a classic appearance can be safely and accurately diagnosed with U/S alone.

## ACKNOWLEDGEMENTS

Authors thank King Abdul-Aziz Specialist Hospital (KAASH), Taif for the opportunity to conduct this study by giving access to the radiology department, laboratory department and archive, also thanks extend to Dr. Nahla Faizo and Dr. Rana Eisa for their help in reviewing of this work, and to all authors of articles, journals and books from where the literature for this article has been reviewed and discussed.

## REFERENCES

- Bolandi L, Gaiani S, Benzi G, Zironi G, Rigamonti A, Fuscorni F, Barbara L, 1992.** Ultrasonography and guided biopsy in the diagnosis of hepatocellular carcinoma. *Ital J Gastroenterol*, 24(1): 46-49.
- Brunt EM, 2000.** Grading and staging the histopathological lesions of chronic hepatitis: the Knodell histology activity index and beyond. *Hepatology J*, 31(1): 241-246.
- Ferenci P, Fried M, Labrecque D, Bruix J, Sherman M, Omata M, Heathcote J, Piratsivuth T, Kew M, Otegbayo JA, Zheng SS, Sarin S, Hamid S, Modawi SB, Fleig W, Fedail S, Thomson A, Khan A, Malfertheiner P, Lau G, Carillo FJ, Krabshuis J, Le Mair A, 2010.** World Gastroenterology Organization guidelines. Hepatocellular carcinoma: A global perspective. *J Gastrointest in Liver Dis*, 19(3): 311-317.
- Gerstenmaier JF, Gibson RN, 2014.** Ultrasound in chronic liver disease. *Insights Imaging J*, 5(4): 441-455.
- Hapani H, Kalola J, Trivedi A, Chawla A, 2014.** Ultrasound evaluation of focal hepatic lesions. *IOSR J Dental Med Sci*, 13(12): 40-45.
- Hima BP, Shukla AK, Krishnappa N, 2014.** Sonographic evaluation of focal and diffuse hepatic lesions. *J Evolut Med Dental Sci*, 3(45): 11114-11129.
- Kemeny N, Fata F, 1999.** Arterial, portal, or systemic chemotherapy for patients with hepatic metastasis of colorectal carcinoma, *J Hepatobiliary Pancreatic Surg*, 6(2): 39-49.
- Kemp SD, Panciera DL, Larson MM, Saunders GK, Werre SR, 2013.** A comparison of hepatic sonographic features and histopathologic diagnosis in canine liver disease. *Internal Med J*, 27(1): 806-813.
- Liang P, Cao B, Wang Y, Yu X, Yu D, Dong B, 2005.** Differential diagnosis of hepatic cystic lesions with grey-scale and colour Doppler sonography. *J Clin Ultrasound*, 33(3): 100-105.
- McClune AC, Tong MJ, 2010.** Chronic hepatitis B and hepatocellular carcinoma. *Clin Liver Dis J*, 14(3): 461-476.
- Mobarak L, Nabeel MM, El Agawy W, 2015.** Risk factors of hepatocellular carcinoma in Egyptian patients with chronic liver disease. *Al-Azhar Assiut Med J*, 13(4): 89-94.
- Parkin DM, Pisani P, Ferly J, 1999.** Estimates of the worldwide incidence of 25 major cancers in 1990. *Int J Cancer*, 80(1): 827-841.
- Ranjan R, Singh BN, 2017.** Evaluation of focal hepatic lesions by using ultrasound evaluation. *Int J Med Health Res*, 3(9): 133-134.
- Sinan T, Sheikh M, Chisti FA, Al Saeed O, Sheikh Z, Hira PR, Behbehani A, 2002.** Diagnosis of abdominal hydatid cyst disease: The role of ultrasound and ultrasound guided fine needle aspiration cytology. *Int J Med Principles Pract*, 11(4): 190-195.
- Smit JN, 2017.** Ultrasound-based navigation for surgical removal of liver lesions. University of Twente. Master thesis. Chapter one, 1-86. (Accessed on Jun 23, 2018 )
- Thimmaiah VT, 2014.** Evaluation of focal liver lesions by ultrasound as a prime imaging modality. *Schol J Appl Med Sci*, 1(6): 1041-1059.
- Torzilli G, Belghiti J, Makuuchi M, 2004.** Differences and similarities in the approach to hepatocellular carcinoma between Eastern and Western institutions. *Liver Transpl J*, 10(2 Suppl 1): S1-S2.
- Van Cutsem E, Cervantes A, Nordlinger B, Arnold D, 2014.** Metastatic colorectal cancer: ESMO Clinical Practice Guidelines for diagnosis, treatment and follow-up. *Ann Oncol*, 25(3):1-9.
- Yang PM, Sheu JC, Huang GT, 1986.** Ultrasonographic appearance of the surface changes of the liver- It's accuracy and value in the diagnosis of liver cirrhosis. *Chin J Gastroenterol*, 9(3): 105-113.

---

**Citation:** Mohammed Ahmed RM, Alkathiri S, Altalhi W, Eid H, Alshalwai M, Alotaibi S, 2020. Differential diagnosis of focal hepatic lesions using ultrasound confirmed with histopathology. *Int Res J Med Med Sci*, 8(2): 18-24.

---