

Topographical anatomy and morphometrical analysis of the pharyngeal orifice of the Eustachian tube: A cadaveric study

Hanan J. Alzahrani^{1*}, Afnan J. Alzahrani² and Wafa'a S. Ramadan¹

¹Faculty of Medicine, King Abdulaziz University, Jeddah, Saudi Arabia

²Faculty of Science, King Abdulaziz University, Jeddah, Saudi Arabia.

Accepted 12 August, 2020

ABSTRACT

The auditory tube (Eustachian tube) is a highly functional organ that works as a channel between the middle ear and the nasopharynx and has three major functions; protection, clearance, and ventilation, each of which depends on a specific structural part. In order for the tube to work and function correctly and normally, the middle ear has to be healthy. Many of the complications and middle ear diseases with increasing prevalence are affected by various factors that cause disturbances in the Eustachian tube functions. The anatomical differences of the Eustachian tube among the multiple age groups could explain the functional differences between them. The limited access to the Eustachian tube is one of the reasons that anatomical uncertainty of the tube still exists therefore, we studied and measured the morphometric parameters of the pharyngeal orifice of the auditory tube and its anatomical variation importance as a landmark in 50 specimens of adult cadavers in total and also explained the results statistically by using means, averages, standard deviations and correlation coefficient. The findings of this study are needed and should be taken into account as established anatomical data before performing some otorhinolaryngeal procedures so that undesired interventions and clinical outcomes could be avoided. Also, the results will play a significant role in understanding the tube dysfunction and the etiological paths of the middle ear diseases and disorders which would be beneficial in planning the best surgical treatments of these ailments.

Keywords: Auditory tube, Eustachian tube, middle ear, nasopharynx, pharyngeal orifice, anatomical morphometry, Eustachian tube injury.

*Corresponding author. E-mail: Zh.anan@hotmail.com.

INTRODUCTION

The auditory tube (Eustachian tube) is an organ which works as a channel between the middle ear and the nasopharynx consisting of two main parts, the short bony section which about 12 mm long and the 24 mm fibrocartilaginous part that has a small portion placed below the lateral wall of the nasopharynx (Bluestone, 2005a). These two parts are connected by a narrow part called isthmus which manages the air intake (Bluestone, 2005a). The auditory tube is a functionally high organ and

has three major functions; each one depends on a specific structural part. The lining epithelium of the lumen of Eustachian tube varies from one part to another and has a role in protecting the middle ear from infections (Tewfik, 2020). Normally, the Eustachian tube is closed, except for the purpose of the ear and the mucosa preservation from the abrupt pressure which affects the vibration of ossicles. When pressure is balanced between the inside and outside the tympanic cavity via a protective

mechanism involving the closing and opening movements of the auditory tube along with soft palate muscles actions during flowing of the air from the nasopharynx to the middle ear which happened by yawning or swallowing (Doyle, 1985; Bento et al., 1998; Ankolekar et al., 2013). Disturbances in the functions of the Eustachian tube, which are protection, clearance and aeration of middle ear, leads to Eustachian tube dysfunction which subsequently could lead to hearing impairment, tubal dysfunction or many infections such as otitis media (OM) which are very common pathologies in children. A study revealed that about 70% of children develop one or more of auditory tube dysfunction and otitis media mostly in their first two years (Kobayashi et al., 2009). In comparison with adults, children have larger adenoids with shorter and more horizontal tubes which explain the high prevalence of Eustachian tube dysfunction in the pediatric population (Poe and Kujawski, 2002; Healy and Rosbe, 2003). All these studies point to the importance of the auditory tube and its functions. As much uncertainty still exists about anatomical studies of adults' auditory tube due the limited access to the Eustachian tube, it has become required to study the auditory tube morphometric especially in adults which will play a significant role understanding its dysfunction and the etiological paths of its diseases and that would be beneficial in planning the best surgical treatments of these diseases and disorders.

LITERATURE REVIEW

Auditory tube (Eustachian tube) anatomy

There are two main portions to the auditory tube, the lateral bony portion (about 12 mm) and the anteromedial cartilaginous portion (about 24 mm), both of which have a cone-like shape, meeting together in the narrowest part of the Eustachian tube which is called isthmus that has a diameter average in adults of 0.5 to 1.5 mm (Ishijima et al., 2000) (Figure 1). The tube in adults has a length that ranges from 31 to 38 mm deviates from the horizontal plane about 30 to 40 degrees and starts from the lateral wall of nasopharynx passing through the petrous part of the temporal bone as an inverted S-shaped path (Graves and Edwards, 1944; Bluestone, 2005b). These two turns in the tube's path start from the tympanic cavity curving through the space between the bony external acoustic meatus in the mandibular condyle and the carotid wall, with another minor curve before the pharyngeal orifice (Graves and Edwards, 1944). Approximately 20 mm above the hard palate lies the nasopharyngeal terminus and an epithelium layer covering the nasopharynx (Proctor, 1967). The torus tubarius, which is formed by the anteromedial cartilaginous end that protrudes into the nasopharynx and raise the nasopharynx mucosa, could

not be seen endoscopically unlike the mucosa suggesting the need for more anatomical measures studies are needed (Proctor, 1967; Smith et al., 2016; Tewfik, 2020). As the tube remains closed at rest status, it opens frequently upon activities such as swallowing, yawning, chewing, and valsalva maneuver technique or atmospheric pressure changes by contraction of the paratubal muscles (Ishijima et al., 2000, Tewfik, 2020).

Lumen and Isthmus

The tube lumen divided into two portions, the bony portion and the cartilaginous portion which the nasopharyngeal and the tympanic cavities area at their widest ends. The Eustachian tube formed an angle through its path from the nasopharynx to the middle ear that about 45 degrees which is a summation of the angle between the luminal top and its base (20 degrees) and the angle between carinal base and luminal roof (Proctor, 1967). The nasal orifice is 8.5 mm high in adults which declines to the 3.5 mm as the tube enters the petrous part of the temporal bone (Proctor, 1967). The Eustachian tube lumen has a triangular shape that is about 2-3 mm vertically and 3-4 mm horizontally which is narrows the most at the isthmus while any broadening in the isthmus would lead to insufficiency in the ear protection function as it prevents the nasopharyngeal secretion from entering into the middle ear (Graves and Edwards, 1944; Tewfik, 2020).

The mucous membrane

The ciliated epithelium that covers the tube lumen has the main role of clearing the middle ear from either the normal middle ear cavity secretions or from the infectious particles and trash it into the nasopharynx with the help of goblet cells. The goblet cells are about 20% of the total cells and secrete (with mucus glands) the mucus that carries these particles away as it contains immunoglobulins, mucopolysaccharides, and lysozyme, any variation in these components concentration would affect the Eustachian tube functions as the mucus usually increased if the middle ear has been infected (Graves and Edwards, 1944; Matsune et al., 1996; Kamimura et al., 2000). The tubal mucosa is found in two ends, the distal of the tympanic cavity as well as the proximal end of the nasopharynx. The mucosal folds in the inferior parts of the tube present in a greater amount than in the superior parts, which increases the mucosa in the base more than the roof as it contains copious ciliated cells, glands, and goblet cells (Graves and Edwards, 1944; Orita et al., 2002). As mentioned previously, with the age increase these folds gradually declined in concentration along with the mucus-producing cells. However, the

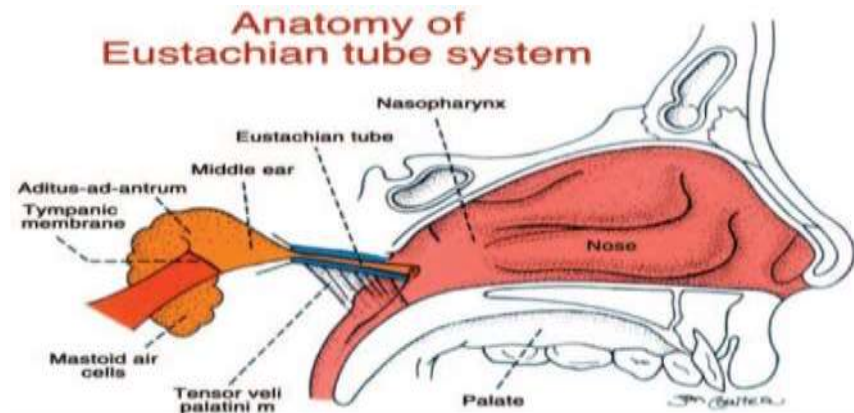


Figure 1. The Eustachian tube involved in a connected structured system which contains, nasopharynx, palate, middle ear, the nose, and mastoid air cells at its distal end. *figure's rights belong to Bluestone (2005b).

studies revealed that the inferior parts of the lumen probably contribute in the drainage and clearance functions due to the increased mucosal folds whereas the superior parts, which are covered with cuboidal ciliated cells, involved in the ventilation function due to the lymphoid tissue association in the mucous (Matsune et al., 1996; Orita et al., 2002; Ozturk et al., 2011). These lymphoid tissues initiate from the lymphocytes extravasation from post-capillary venous called high endothelial venules (HEV) (Matsune et al., 1996; Orita et al., 2002; Ozturk et al., 2011).

Cartilaginous portion

The cartilaginous part is structurally similar to the nose cartilage, and it binds with the skull base and bends further between the sphenoid bone greater wing and the petrous part of the temporal bone to form a flange called sulcus tubae which has a groove-like shape with 40 degrees angle related to the transverse plane and 45 degrees to the horizontal plane (Bluestone, 2005b; Proctor, 1967). It is strongly attached from its other end (lateral posterior end) by a 3 mm fibroextension into the bony part as they join together at the isthmus while the inferomedial end is connected to the posterior point of the medial pterygoid lamina (Proctor, 1967).

Lateral membranous wall

The lateral membranous wall consists of fiber tissues, but it is mainly mentioned without well-defined description in the cartilaginous middle part of the tube as it associates with the lumen function. Apparently, it is attached to the inferior groove of the lateral cartilaginous arm representing the luminal submucosa with its medial

margin while a connective tissue layer representing the entrance of the tensor veli palatine muscle. The posterior section between these two edges filled with adipose tissue while the anterior section occupied by the glandular tissue (Graves and Edwards, 1944).

Ostmann's fat pad

The fatty bodies are located in the inferolateral part of the tube with main function of keeping the tube closed at rest. Its mass becomes bigger in children due to the height increasing of the pad after birth (Takasaki et al., 2002). It usually reduces the tubal opening when the lateral lamina moves by the contraction of the tensor veli palatini muscle to the superior direction of the tubal lamina (Takasaki et al., 2002).

The osseous portion

The osseous or bony part is about 12 mm long and its medial wall divides to labyrinthine (the poster lateral part) and carotid (anteromedial part) which its shape and size determined by the main supply position (the internal carotid artery) (Bell and Gaillard, 1944). This portion covers with mucosa similar to middle ear mucosa which contains the ciliated cells and the mucus producing cells (Graves and Edwards, 1944). The osseous portion has a linear path starting at tympanic cavity exactly in the carotid wall passing through the squamous and the temporal bone petrous part as it forms a slight curve while continuing to follow the superior portion's anterior wall of the middle ear to form an edge at its end. This edge forms in order to bind the osseous part to the cartilaginous part with 160 degrees (in total) angle when they come across an irregular bony surface in their

joining point (Graves and Edwards, 1944; Djerić and Savić, 1985).

Muscles

In case of chewing, yawning, or swallowing, the tube opening shifts from its main rest status (closed) and start to open to equalize the pressure in the middle ear. This tube opening process involves the contribution (directly or indirectly) of the four-tube muscles: the tensor veli palatine muscle as the main dilatator of the tube with the assistance of the levator veli palatini muscle, the tensor tympani, and the salpingopharyngeus while the structures that is responsible of the tube closing which occurs by the force of surrounding tissues or the elastic fibers recoil (Ishijima et al., 2000; Swarts and Bluestone, 2003). The tensor veli palatini muscle, which initiated from the fibrolateral wall and the superior cartilaginous part and exerts a force that will form the sulcus tubarius which enters into the cartilaginous portion as it acts as dilatator of the tube thereby, the tube would not open properly in case of ineffectiveness of the muscle (Honjo et al., 1983; Swarts and Bluestone, 2003). In addition, the tensor veli palatini muscle opening active indirectly affected by the tensor tympanic muscle action on the stretch receptors of the tympanic membrane in the equalization of the middle ear pressure (Honjo et al., 1983). The levator veli palatini muscle, which is derived from the medial cartilaginous part into the soft palate, support the tensor veli palatini muscle by raising the medial cartilaginous arm at the nasopharyngeal end and turn the medial lamina during the contraction to open the anterior part of the cartilage (Ishijima et al., 2002). Whilst swallowing, the salpingopharyngeus muscle, which originates from the inferior and the medial cartilaginous part and is attached to the pharyngeal end forming a triangular shape, has a role in raising the pharynx (Swarts and Bluestone, 2003; Tewfik, 2020) (Figure 2).

Innervation

Generally, the innervation of the tube mostly by the glossopharyngeal nerve. the tympanic plexus supplies the osseous part while the cartilaginous part is innervated by the pharyngeal branch of the pterygopalatine ganglion and the meningeal branch of the mandibular nerve (Bell and Gaillard. 1994). Moreover, a branch derived from the otic ganglion, sphenopalatine nerve, and pharyngeal plexus supplies the tubal pharyngeal surface and the tympanic and pharyngeal plexuses supplies the rest of the tube (Nathanson and Jackson, 1976). In addition, the sphenopalatine ganglion, otic ganglion, glossopharyngeal nerves, petrosal nerves, and caroticotympanic nerve, all of these together support the sympathetic innervation

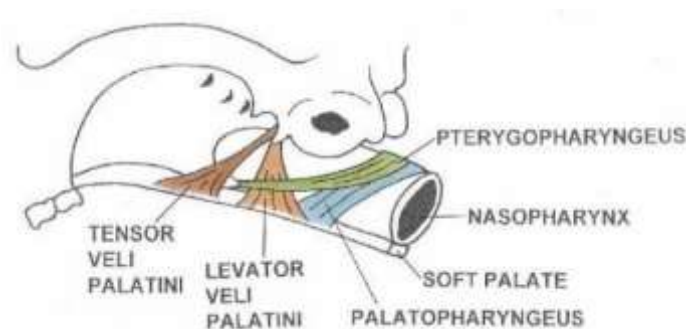


Figure 2. Anatomy of the tube four muscles. *figure's rights belong to Bluestone (2005b).

whereas the parasympathetic nerve supplied by the vidian nerve from the sphenopalatine ganglion (Nathanson and Jackson, 1976). As for the muscles, a mandibular nerve, the ipsilateral trigeminal motor nucleus ventromedial part specifically, innervated the two muscles (the tensor veli palatini muscle and tensor tympani muscle) and the vagus nerve, which derived from the nucleus ambiguus, supports the other muscle (the levator veli palatini) (Ishijima et al., 2002).

Blood supply

The tube receives blood supply by five main arteries: as a branch of facial artery the ascending palatine artery, the artery of the pterygoid canal and the pharyngeal branch are all from the maxillary artery third part, the ascending pharyngeal artery as a branch of the external carotid artery, and the middle meningeal artery which is a branch from the first part of maxillary artery while the waste is carried via the pterygoid venous plexus (Figure 3 and 4) (Graves and Edwards, 1944). Furthermore, the blood vessels are far away from the mucous membrane floor in the bony part of the tube and they are in the superior petrous part more than the mesotympanum and the hypotympanum of the middle ear which indicate the role of the superior petrous in the gas exchange function (Matsune et al., 1991).

Lymphatic system

There is a lymphatic system within the tubal mucus membrane, mostly in the cartilaginous part more than the bony part, which is how its own waste is carried into the retropharyngeal lymph nodes (Graves and Edwards, 1944; Tewfik, 2020).

Eustachian tube's functions and physiology

Protection, clearance, and ventilation are the three main

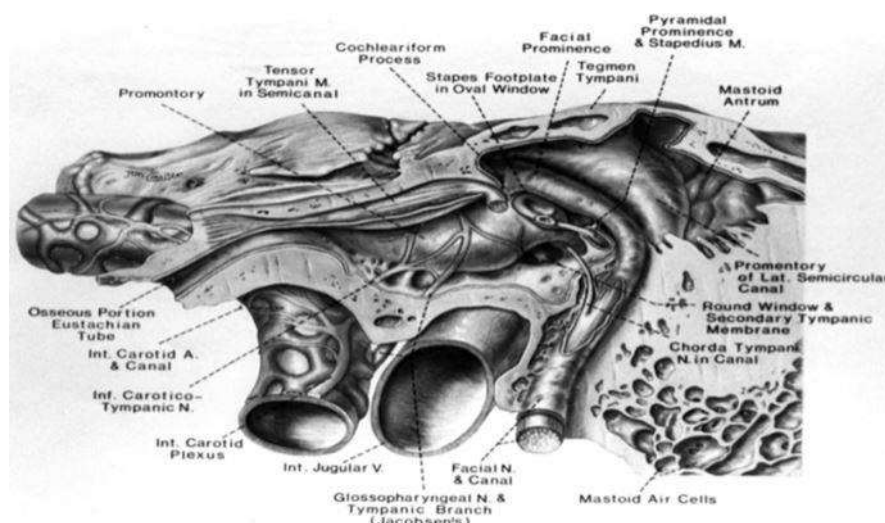


Figure 3. The middle from the lateral to medial (the tubal bony part, the tensor tympani muscle, glossopharyngeal nerve, and the tympanic plexus. *figure's rights belong to Bluestone (2005b).

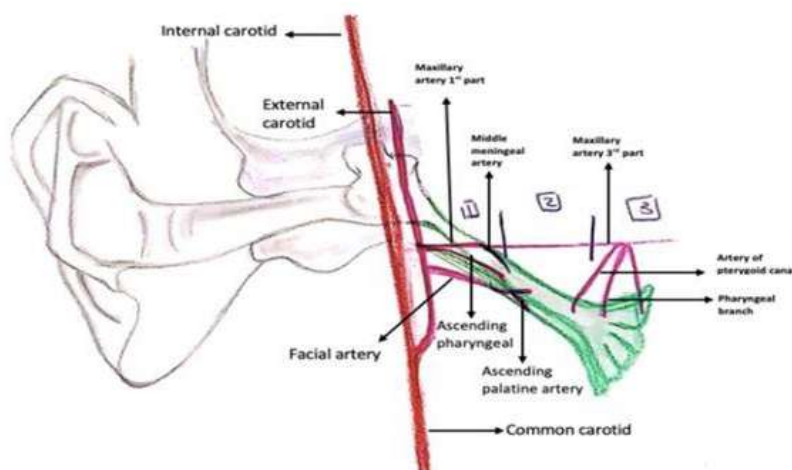


Figure 4. The tube blood supply arteries. * Figure's rights belong to Hanan Alzahrani

functions of the Eustachian tube. A disturbance of the Eustachian tube would cause insufficiency of these functions. This tube disturbance is a consequence of different reasons and factors which could lead to complications.

Protection function

The Eustachian tube is usually closed at rest to protect the middle ear from the atmospheric pressure changes, but in case of chewing, yawning or swallowing, it starts to open as the tube muscles contract to protect the middle

ear by equalizing the middle ear pressure (Price, 2000). The tube can protect the middle ear not only from the pressure changes but also preventing the nasopharyngeal secretions from entering into the middle ear using either the mechanical way by the flowing mucus or the immunological way by stimulating the effectors and memory lymphocytes secretions to kill the pathogens, or by using the surfactant opsonin proteins to ease the phagocytosis (Price, 2000; Haagsman and Diemel, 2001). In some cases or as a result of variations in the tube anatomy such as patulous Eustachian tube, Down's syndrome, cleft palate children, or tube shortness in children, the nasopharyngeal secretions which may

contain infectious particles could be reflux into the middle ear causing infections (Ayanoglu et al., 2004). In another way, the disturbance of the protection function might lead to otitis media due to pathogens accessing the middle ear (Swarts and Bluestone, 2003). Moreover, the middle ear could be damaged when it exposures to the pressure changes that could causes autophonia (Swarts and Bluestone, 2003).

Clearance function

The mucociliary transporting system is responsible for the clearance function which consists of ciliated epithelium, the mucus, mucus glands, goblet cells, lymphoid tissues, and several capillaries. The secretion of these glands and cells along with the repeated beating movement of ciliated epithelium carries away all the infectious particles, pathogens, even the dead cells, into the nasopharyngeal end (Houtmeyers et al., 1999). Any defect of any of the mucociliary transporting structures affects the clearance function of the tube. Honjo and colleagues mentioned another tube clearance mechanism by the repetitive contraction and relaxation muscles movement causing the lumen to enlarge and narrow which eventually clears the waste and the secretions that was sucked into the tube due to the lumen negative pressure, during swallowing or yawning, to the nasopharyngeal end (Honjo et al., 1985). The viruses and pathogens that enter the tube lumen contain endotoxins in their secretion which causes the motility ciliated cells to be disrupted which leads to ineffective clearance of the ear. Generally, the ineffective clearance of the pathogens that comes from the nasopharyngeal indicates a dysfunction in the mucociliary transporting system which has many factors such as ciliary dyskinesia, cystic fibrosis, allergy or irradiation that eventually causes otitis media with effusion (Downs et al., 2001). If there is any insufficiency in the muscular clearance, it is usually a result of disruption of paratubal muscles insertion or defective tubal opening (Downs et al., 2001).

Ventilation function

The paratubal muscles contract to open the Eustachian tube and in the meantime the surfactant that is secreted by the tubal epithelium which contains surface tension lowering phospholipids that helps to decrease the opening pressure (Paananen et al., 1999). The active opening of the tube lets the airflow through the middle ear to ventilate its cavity, equalize the pressure changes, and allow the ear mucosa to absorb ate the gas by the surrounding tissues, therefore, the disruption of these functions may cause a negative pressure in the middle ear (Doyle and Seroky, 1994). Defective paratubal

muscles contraction and insertion, changes in tubal elasticity, tubal anatomical defects, or tubal surfactant deficiency can cause failure in tubal opening, consequently, the tube lacks the proper ventilation (Downs et al., 2001; Matsune et al., 1996). As the tubal opening failure have a high rate in children, and patients with cleft palate, sometimes the tube is blocked or has obstruction as a result of inflammation, infection, or allergic reaction that causes the mucosa, enlarged the nasopharyngeal tonsil (adenoids), or nasopharyngeal carcinoma (Matsune et al., 1996). These problems indicate the importance of a normal anatomical tube to function properly.

METHODOLOGY

In order to identify the location of the auditory tube orifice in relation to the surrounding structures. 50 specimen measurements taken (in total) which the right and left sagittal head and neck sections of adult fixed by formalin, 22 of them were taken from only the left side while 25 from the right side and 2 specimens measurements from both sides (complete specimens). The specimens were obtained from the Anatomy Department of the Faculty of Medicine, King Abdul-Aziz University in Jeddah. Gender, race and age were not taken into account. The anatomical landmarks between the auditory tube and the surrounding various anatomical landmarks were measured using a digital ruler Helios-preisser. A datasheet was created using Excel Microsoft software to record and calculate the means, averages, and standard deviations of the information obtained by measuring the distances between the auditory tube orifice and those anatomical points. IBM SPSS software was used as a statistical analytical tool to analyze the relationship between longitudinal and vertical diameters of the auditory orifice by measuring the correlation coefficient of the data (Table 1 and Figure 5).

RESULTS

Isolated specimens

The distance from the auditory tube orifice to the inferior choana midpoint showed an average of 4.02 ± 3.69 mm and of 4.41 ± 3.29 mm on the left side specimens and the right side respectively which as it showed the AT-C was minimally lower on the left side than the right side as well as the distance from the auditory tube orifice to the anterior nostril midpoint with a left-side average 52.77 ± 6.33 mm and a 56.45 ± 6.61 mm average on the right side. On the contrary, the distance from the auditory to the soft palate center point was slightly higher on the left side with the average 4.64 ± 3.83 mm and 4.83 ± 3.15 mm on the right side. The average of distance from the auditory tube to the uvula center was 23.85 ± 4.05 mm on the left which was higher than the right side which was 25.42 ± 6.37 mm. On the right side specimens' average was higher when the distance from the auditory tube the base of the skull was measured which showed $9.33 \pm$

Table 1. The abbreviations of studied points and the distances.

Abbreviation of studied point	Description of studied point	Abbreviation the distance	Description of the distances
C	Inferior choana midpoint	AT – C	From the auditory tube orifice to inferior choana midpoint
N	The anterior nostril midpoint	AT- N	From the auditory tube orifice to the anterior nostril midpoint
SP	Soft palate center point	AT – SP	From the auditory tube orifice to soft palate center point
U	Uvula center point	AT- U	From the auditory tube orifice to uvula center point
AT	Auditory tube orifice with its length (L) and width (W)	AT- SB	From the auditory tube orifice to the base of the skull (the upper border of C1 vertebra).
SB	The base of the skull (the upper border of C1 vertebra).	L	The length of the auditory tube orifice
		W	The width of the auditory tube orifice.

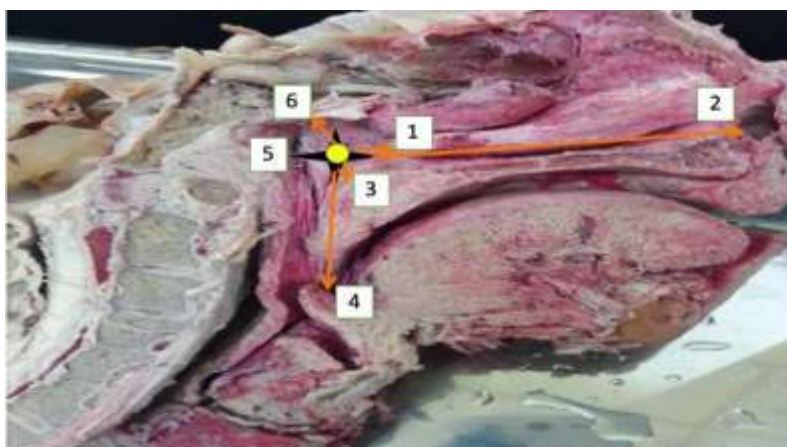


Figure 5. Measurements taken from various landmarks on the medial surface of the sagittal head and neck sections to determine the position of the auditory tube and other anatomical points for measurements. *The photo was taken by Hanan Alzahrani during measurement procedure.

4 mm while on the left side was 6.21 ± 2.2 mm. It has also been found that the average length and width of the tube orifice on the left were 3.48 ± 2.05 mm and 4.87 ± 2.08 mm respectively whereas on the right side were 6.6 ± 2.93 mm length average and 5.59 ± 3.07 mm width average which showed that the length average was higher on the left while the width average was higher on the right (Table 2, Figures 6 and 7).

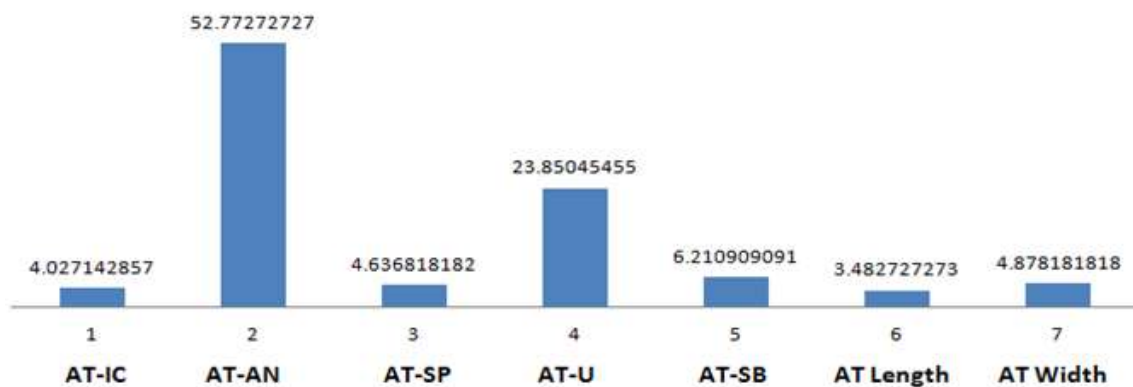
Complete specimens

In the complete specimens, the measurements were taken from both side (left and right) and it has been found that unlike the isolated specimens the distance from the auditory tube orifice to the inferior choana midpoint was

slightly higher on the left side with 88 ± 2.52 mm average and 1.65 ± 0.16 mm average on the right side. However, the distance from the auditory tube orifice to the anterior nostril midpoint was lower on the left side than the right side as the average of the left side was 49.58 ± 0.42 mm and was 50.82 ± 2.22 mm on the right side. The average of the distance from the tube orifice to the soft palate center was 0.69 ± 0.4 mm on the left side which was lower than 3.81 ± 3.6 mm of the right side as well as the distance from the auditory tube orifice to uvula center which was also lower on the left side with 20.295 ± 3 mm average and 22.64 ± 2.07 mm average on the right. The distance from the auditory tube orifice to the base of the skull displayed an average of 8.175 ± 1.06 mm on the left side and 9.22 ± 1.1 mm on the right side which showed that the AT-SB was lower on the right side. Finally, the

Table 2. Distances measured expressed as mean, Standard deviation (SD), maximum and minimum values recorded in isolated specimens.

Distance	The side	Mean (mm)	Standard deviation (mm)	Maximum (mm)	Minimum (mm)
AT-IC	RT	4.41	3.29	12.56	0.32
	LT	3.69	4.02	16.63	0.03
AT-AN	RT	56.45	6.61	69.62	45.52
	LT	52.77	6.33	30.34	61.29
AT-SP	RT	4.83	3.15	12.36	0.2
	LT	4.64	3.83	14.67	0.31
AT-U	RT	25.42	6.37	38.53	11.27
	LT	23.85	4.05	30.1	15.6
AT-SB	RT	9.33	4	16.78	3.44
	LT	6.21	2.2	11	2.53
AT Length	RT	3.48	2.05	81.99	0.39
	LT	2.93	6.6	12.23	0.65
AT Width	RT	5.59	3.07	11.14	0.39
	LT	4.87	2.08	9.76	1.67

**Figure 6.** Mean of distances on left side isolated specimens measured in mm.

AT-IC LT side = 3.69 mm; **AT-AN** LT side = 52.77 mm; **AT-SP** LT side = 4.64 mm; **AT-U** LT side = 23.85 mm; **AT-SB** LT side = 6.21 mm; **AT Length** LT = 2.93 mm; **AT Width** LT = 4.87mm.

length of tube orifice has a higher average on the left side which is about 2.475 ± 0.48 mm and it was 8.395 ± 2.47 mm on the right side while on the other hand, the width was higher on the right side with 4.95 ± 0.07 mm average and 3.915 ± 1.19 mm on the left (Table 2, Figure 8).

DISCUSSION

Our anatomical development and growth are affected by

many factors and evolution was one of the main factors that established differences in the human body as years passed. Based on this, we hypothesized that the anatomical measurements of the Eustachian tube could be different from those that measured 25 years ago. We found that the values of the AT-IC, AT-AN, AT-SP, AT-U, AT-SB, AT length and width were within the same range with an obvious difference on either side in isolated specimens and minimal difference in complete specimens. The results displayed that the diameters of

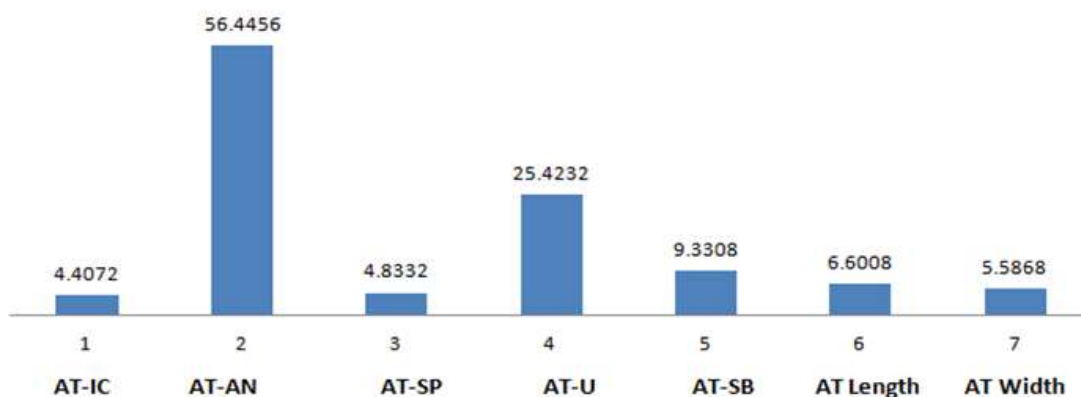


Figure 7. Mean of distances on right side isolated specimens measured in mm.
AT-IC RT side = 4.41 mm; **AT-AN** RT side = 56.45 mm; **AT-SP** RT side = 4.83 mm; **AT-U** RT side = 25.42 mm; **AT-SB** RT side = 9.33 mm; **AT Length** RT = 3.48 mm; **AT Width** RT = 5.59 mm.

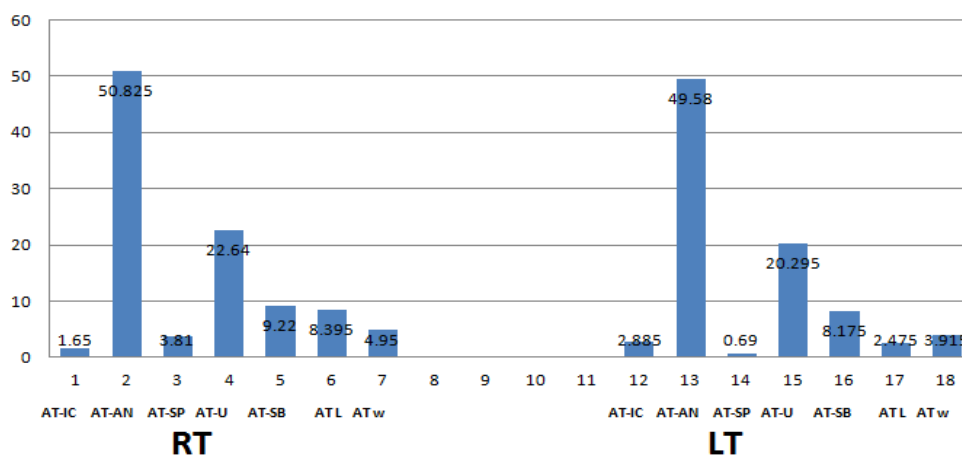


Figure 8. Mean of distances on both sides in complete specimens measured in mm.
AT-IC RT side = 1.65 mm **AT-IC** LT side = 2.88 mm
AT-AN RT side = 50.82 mm **AT-AN** LT side = 49.58 mm
AT-SP RT side = 3.81 mm **AT-SP** LT side = 0.69 mm
AT-U RT side = 22.64 mm **AT-U** LT side = 20.295 mm
AT-SB RT side = 9.22 mm **AT-SB** LT side = 8.175 mm
AT Length RT = 8.395 mm **AT Length** LT = 2.475 mm
AT Width RT = 4.95 mm **AT Width** LT = 3.915 mm.

the auditory orifice to the surroundings (especially from auditory orifice to the inferior choana, and the anterior nostril midpoint) had a positive linear association which means that augmentation of one diameter was associated with the augmentation of the other in a parallel manner so that the symmetrical position of the auditory orifice was obtained (Table 3, Figure 9). This may present the importance of the normal size of the tube for a perfect function without dilation or incompetence with their effect on recurrent otitis media, recurrent pharyngitis, upper respiratory tract infections with later on prolonged condition of hearing problems from advanced dysfunction. We noticed that there was a

Table 3. Correlation between the corresponding distance on the right and left side specimens.

Dimension	Correlation
RT & LT AT-IC	0.378
RT & LT AT-AN	-0.078
RT & LT AT-SP	0.254
RT & LT AT-U	0.342
RT & LT AT-SB	-0.212
RT & LT AT Length	-0.29
RT & LT AT Width	-0.167

* Correlation is significant at the 0.01 level (2-tailed).
 ** Correlation is significant at the 0.02 level (2-tailed).

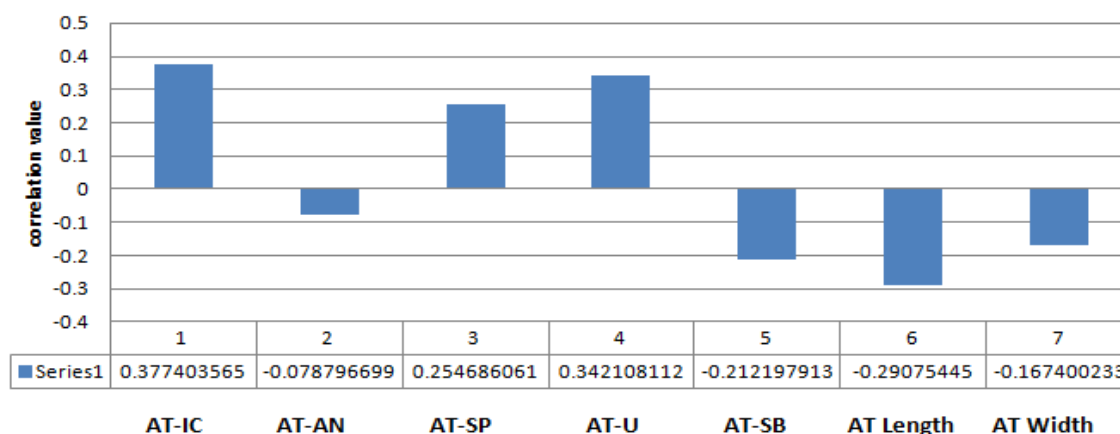


Figure 9. Correlation between the same dimensions on both opposing sides in isolated specimen.

positive linear correlation between each of the AT-C, AT-SP and AT-U on the right side with their opposite equivalent on the left side; whereas the correlation was a negative linear between each of the AT-N and AT-SP on the right side with their counterpart on the left side (Table 3, Figure 9). The AT length and width on the right side had a negative linear correlation with the AT length and width on the left side (Table 3, Figure 9). Regarding the complete specimens in the study, we measured the distance from the AT to the inferior choana, anterior nostril midpoint and the base of the skull (the upper border of C1 vertebra), It was found that these distance measurements on the right side had a positive linear correlation with their counterpart measurements on the left side and vice versa (Table 4, Figure 10). On the contrary to other diameters, the distance from the AT to the soft palate, uvula center, length and width on the right side of the tube orifice had a negative linear correlation with their opposite equivalent on the left side (Table 4, Figure 10). To explain our assumption, we compared the result of this study with previous studies. In 2000, a study revealed that the mean of the tube length in 7 adults was 37.00 ± 4.16 which was notably higher than our results that range between 3.48 ± 2.93 mm in isolated specimens (Table 2), 2.48 ± 8.40 in complete specimens which indicates a change in the measurements (Ishijima et al., 2000) (Table 5). According to Ankolekar et al. (2013) results, the average of AT-U and AT-SB were 33.3 ± 31.8 mm and 14.5 ± 11.5 mm respectively which is also significantly higher than the results in this study that range between 25.42 ± 23.85 mm and 9.33 ± 6.21 mm respectively. Any marginal error that could be noticed in future analysis might be due to formalin effect on the specimens. The findings of our study suggest that there is symmetry between all the dimensions of an auditory orifice with the related other anatomical points; although these distances play a role in the maintenance of the orifice symmetrical position, they do not influence the

Table 4. Correlation between the corresponding distances on the complete specimens.

Dimension	Correlation
RT& LT AT-IC	1
RT& LT AT-AN	1
RT& LT AT-SP	-1
RT< AT-U	-1
RT& LT AT-SB	1
RT& LT AT Length	-1
RT& LT AT Width	-1

*Correlation is significant at the 0.01 level (2-tailed)

**Correlation is significant at the 0.02 level (2-tailed).

diameter of the auditory orifice which is more important both clinically and technically. After analyzing the relationship between longitudinal and vertical diameters of the auditory orifice simultaneously in the study, it has been found that only the longitudinal diameter of the auditory orifice had a statistically significant correlation with the vertical diameter of auditory orifice. Symmetry and stable proportions in every position of the auditory orifice should be taken into account as established anatomical data before performing some otorhinolaryngeal procedures so that undesired intervention and clinical outcomes could be avoided. The shortness and the horizontal plane in the Eustachian tube of children explain the commonness of the tube dysfunction in children. The adenoids hypertrophy could cause the tube dysfunction and it is considered as the primary cause of Eustachian tube dysfunction and its complications due to its advanced symptoms such as obstruction, rhinorrhea and recurrent infection which is based on the relation between the dysfunction of the tube and chronic rhinoadenoiditis (Siegel et al., 1988). The tube functional and mechanical obstruction is usually

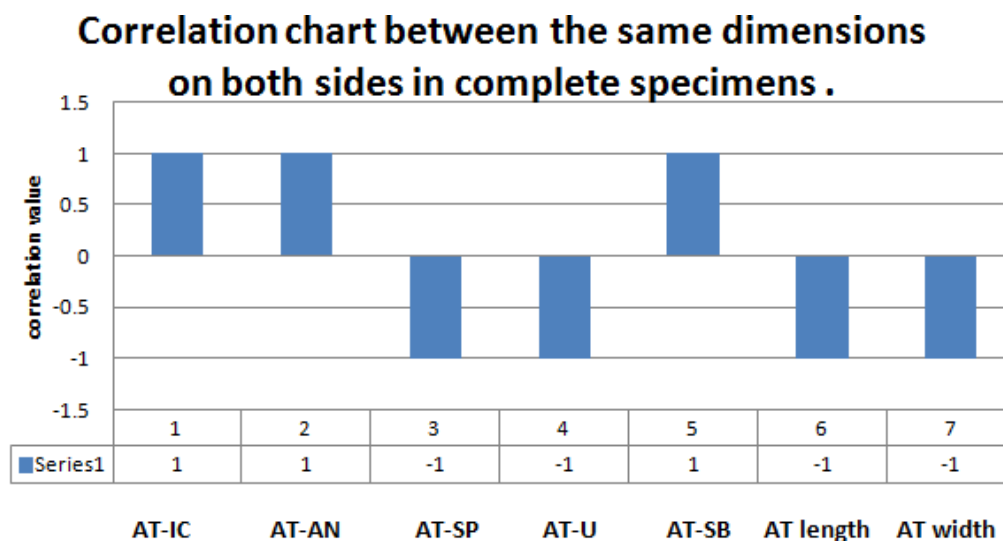


Figure 10. Correlation between the same dimensions on both opposing sides in complete specimen.

Table 5. Distances measured expressed as mean, Standard deviation (SD), values recorded in complete specimens.

Distance	The side	Mean (mm)	Standard deviation (mm)
AT-IC	RT	1.65	0.16
	LT	2.88	2.52
AT-AN	RT	50.82	2.22
	LT	49.58	0.42
AT-SP	RT	3.81	3.6
	LT	0.69	0.4
AT-U	RT	22.64	2.07
	LT	20.295	3
AT-SB	RT	9.22	1.1
	LT	8.175	1.06
AT Length	RT	8.395	2.47
	LT	2.475	0.48
AT Width	RT	4.95	0.07
	LT	3.915	1.19

affected by the adenoids due to the small air from the rhinopharynx as the local pressure gets bigger than the earlier one when the lymphoid tissue appeared (Emerick and Cunningham, 2006). This dysfunction eventually (as it is the main cause in children) causes hypoacusis which is an otic complication which indicates the need of an accurate diagnosis and fast treatment of the various

types of tube dysfunction which considers the correct diagnosis in case of pathologic tympanogram. The middle ear pressure measurements are important in diagnose due to the effect of adenoids obstruction on the ventilation function of the tube. Finally, for proper tube functionality, the adenoids the tube dysfunction should be resolved.

Conclusion

The morphometric measurements of the Eustachian tube differ from those obtained 20 years ago. It could be evolution or many other factors affecting our anatomy. We suggest that similar studies take place at least every 10 years. The results clarify the important role of the auditory tube dimensional measurements and its position for proper aeration of the middle ear and providing effective treatments to the causes of tubal otitis media. The findings and data can also be beneficial in otorhinolaryngological surgeries.

Acknowledgement

The authors^{1,2} would like to thank their mother who helped them all the way and in every step. They also thank Ms. Wala'a A. Bahajri for reviewing the manuscript and for her useful suggestions.

REFERENCES

- Ankolekar** VH, Mamatha H, D'Souza A, Sushma R, D'Souza AS, **2013**. Morphometric study of pharyngeal orifice of auditory tube and its clinical relevance. *The Exp*, 16: 1134-1137.
- Ayanoglu** E, Uneri C, Turoglu T, Dogan V, **2004**. Reflux of nasopharyngeal content into middle ear through the eustachian tube. *Eur Arch Otorhinolaryngol*, 261: 439-444.
- Bell** DJ, **Gaillard** F, **1994**. Eustachian tube [Online]. radiopaedia.org. Available: <https://radiopaedia.org/articles/eustachian-tube> [Accessed 22 June 2020].
- Bento** R, Miniti A, Marone S, **1998**. Tuba auditiva. *Tratado de Otolgia*. 1ª edição. São Paulo: Edusp, 173-182.
- Bluestone** CD, **2005a**. Humans are born too soon: impact on pediatric otolaryngology. *International journal of pediatric otorhinolaryngology*, 69, 1-8.
- Bluestone** MB, **2005b**. Eustachian tube: structure, function, role in otitis media, PMPH-USA.
- Djerić** D, **Savić** D, **1985**. Anatomical variations and relations of the bony portion of the eustachian tube. *Acta oto-laryngologica*, 99, 543-550.
- Downs** BW, Butehorn HF, Prazma J, Rose AS, Stamat JC, Pillsbury III, HC, **2001**. Action of histamine on eustachian tube function. *Otolaryngol Head Neck Surg*, 124, 414-420.
- Doyle** W, **1985**. Physiology: introduction. *Ann Otol Rhinol Laryngol*, 120.
- Doyle** WJ, **Seroky** JT, **1994**. Middle ear gas exchange in rhesus monkeys. *Ann Otol Rhinol Laryngol*, 103, 636-645.
- Emerick** KS, **Cunningham** MJ, **2006**. Tubal tonsil hypertrophy: a cause of recurrent symptoms after adenoidectomy. *Arch Otolaryngol Head Neck Surg*, 132, 153-156.
- Graves** GO, **Edwards** LF, **1944**. The eustachian tube: a review of its descriptive, microscopic, topographic and clinical anatomy. *Arch Otolaryngol*, 39: 359-397.
- Haagsman** HP, **Diemel** RV, **2001**. Surfactant-associated proteins: functions and structural variation. *Comp Biochem Physiol A Mol Integr Physiol*, 129, 91-108.
- Healy** G, **Rosbe** K, **2003**. Otitis media and middle ear effusions. *Ballenger's Otorhinolaryngology Head and Neck Surgery*. Hamilton: BC Decker, 249-60.
- Honjo** I, Hayashi M, Ito S, Takahashi H, **1985**. Pumping and clearance function of the eustachian tube. *Am J Otolaryngol*, 6, 241-244.
- Honjo** I, Ushiro K, Haji T, Nozoe T, Matsui H, **1983**. Role of the Tensor Tympani Muscle in Eustachian Tube Function I. *Acta Oto-laryngol*, 95, 329-332.
- Houtmeyers** E, Gosselink R, Gayan-Ramirez G, Decramer M, **1999**. Effects of drugs on mucus clearance. *Eur Respir J*, 14, 452-467.
- Ishijima** K, Sando I, Miura M, Balaban CD, Takasaki K, **2002**. Functional anatomy of levator veli palatini muscle and tensor veli palatini muscle in association with eustachian tube cartilage. *Ann Otol Rhinol Laryngol*, 111, 530-536.
- Ishijima** K, Sando I, Suzuki C, Balaban C, Takasaki K, **2000**. Length of the eustachian tube and its postnatal development: computer-aided three-dimensional reconstruction and measurement study. *Ann Otol Rhinol Laryngol*, 109, 542-548.
- Kamimura** M, Balaban CD, Ganbo T, Sando I, Suzuki C, **2000**. Cellular distribution of mucosa-associated lymphoid tissue with otitis media in children. *Ann Otol Rhinol Laryngol*, 109, 467-472.
- Kobayashi** T, Hasegawa J, Kikuchi T, Suzuki T, Oshima T, Kawase T, **2009**. Masked patulous Eustachian tube: an important diagnostic precaution before middle ear surgery. *Tohoku J Exp Med*, 218, 317-324.
- Matsune** S, Sando I, Takahashi H, **1991**. Insertion of the tensor veli palatini muscle into the eustachian tube cartilage in cleft palate cases. *Ann Otol Rhinol Laryngol*, 100, 439-446.
- Matsune** S, Takahashi H, Sando I, **1996**. Mucosa-associated lymphoid tissue in middle ear and Eustachian tube in children. *Int J Pediatr Otorhinolaryngol*, 34, 229-236.
- Nathanson** SE, **Jackson** R, **1976**. Vidian nerve and the eustachian tube. *Ann Otol Rhinol Laryngol*, 85, 83-85.
- Orita** Y, Sando I, Hirsch BE, Miura M, Hasebe S, Balaban CD, **2002**. Postnatal development of the eustachian tube glands. *Laryngoscope*, 112, 1647-1652.
- Ozturk** K, Snyderman CH, Sando I, **2011**. Do mucosal folds in the eustachian tube function as microturbines? *Laryngoscope*, 121, 801-804.
- Paananen** R, Glumoff V, Hallman, M, **1999**. Surfactant protein A and D expression in the porcine Eustachian tube. *FEBS Letters*, 452, 141-144.
- Poe** D, **Kujawski**, O. **2002**. Endoscopic diagnoses of Eustachian tube dysfunction. Minimally invasive surgery of the ear. Silverstein, Rosenberg, Poe, Eds.
- Price** A, **2000**. Essentials of clinical immunology. *Immunol Cell Biol*, 78, 176-178.
- Proctor** B, **1967**. Embryology and anatomy of the eustachian tube. *Arch Otolaryngol*, 86, 503-514.
- Siegel** M, Sadler-Kimes D, Todhunter J, **1988**. ET cartilage shape as a factor in the epidemiology of otitis media. Recent advances in otitis media: proceedings of the Fourth International Symposium. Burlington: BC Decker, 114-7.
- Smith** ME, Scoffings DJ, Tysome JR, **2016**. Imaging of the Eustachian tube and its function: a systematic review. *Neuroradiology*, 58, 543-556.
- Swarts** JD, **Bluestone** CD, **2003**. Eustachian tube function in older children and adults with persistent otitis media. *Int J Pediatr Otorhinolaryngol*, 67, 853-859.
- Takasaki** K, Balaban CD, Sando I, Miura M, **2002**. Functional anatomy of the tensor veli palatini muscle and Ostmann's fatty tissue. *Ann Otol Rhinol Laryngol*, 111, 1045-1049.
- Tewfik** TL, **2020**. Eustachian Tube Function [Online]. Medscape.com. Available: <https://emedicine.medscape.com/article/874348-overview#showall> [Accessed 13 June 2020].

Citation: Alzahrani HJ, Alzahrani AJ, Ramadan WS, 2020. Topographical anatomy and morphometrical analysis of the pharyngeal orifice of the Eustachian tube: A cadaveric study. *Int Res J Med Med Sci*, 8(3): 97-108.
